



PATIENT

HARDY BALLARD

SPECIES

Canine

BREED

Border Collie Mix

SEX

Neutered Male

AGE

6 Years

INTERPRETED BY

Nele Eley, DVM
Dr. med. Vet. DipECVDI

HOSPITAL NAME

Sierra Pet Clinic

REFERRING VET

Alejandro Garcia,
DVM

INVOICE

46943

DATE

8-10-21

PRESENTING CLINICAL SIGNS

History of chronic intermittent vomiting- at least three months. Lifelong history of sensitive stomach and marginal appetite. Recent exacerbation of clinical signs w/ 4 pound weight loss over six months. Body condition 3.5/9 owner constantly rotates food to encourage appetite. History of tick exposure in June. Lab work in April was within normal limits except for T4= 0.8. Recent onset of loose stool. Current Labs with cPL pending.

RADIOGRAPHIC STUDY OF THE ABDOMEN

Right/left lateral and ventrodorsal views totaling 3 images available for review.

RADIOGRAPHIC FINDINGS

The patient is in thin body condition.

The surrounding bony structures are within normal limits.

The abdominal wall is smooth and thin.

The serosal detail is maintained throughout the peritoneal and retroperitoneal space.

The liver is appropriate in position, size and presents uniform opacity.

The splenic head is in the anticipated position and within normal limits for size and opacity. The splenic body and tail are considered normal for position, size, shape and opacity.

Both kidneys are seen and present with normal size, shape, delineation and opacity. The urinary bladder is in its anticipated position. No radiopaque calculi are noted throughout the upper and lower urinary tract.

The stomach is post-prandial. No abnormal dilation or malpositioning of the stomach is seen. There is a soft tissue opaque cone shaped structure seen within the stomach on right lateral view surrounded by ingesta which is not visible on the left lateral and orthogonal views.

One small intestinal loop appears to be mildly dilated and contains atypical small intestinal content with nearly mineral opaque gravel (see image below).

The large intestine is mainly dilated with gas and contains a moderate amount of fecal material. A wire shaped metal opaque structure is seen within the colon.

RADIOGRAPHIC DIAGNOSIS

- Possible gastric foreign material.
- Small intestinal gravel sign.
- Wire type foreign material within the large intestine - incidental finding.

INTERPRETATION OF THE FINDINGS & FURTHER RECOMMENDATIONS

The findings of the right lateral view suggest potential for foreign material within the stomach; however, this is not confirmed in the complementary views, and I cannot rule out summation



PATIENT

HARDY BALLARD

SPECIES

Canine

artifact here. There also appears to be a small intestinal gravel sign which supports the potential for longer standing functional ileus or mechanical subileus within the small intestine. The plain radiographic findings are not finally conclusive and further definition is required. A first step could be to repeat the plain radiographs with the patient being NPO and potentially add positive contrast media in order to verify the gastric changes and gain more information about the gastric and small intestinal transit times. However, full abdominal ultrasound with the patient being NPO could provide similar information with the advantage of also providing information about the remainder of the abdominal organs, gastrointestinal tract's wall and motility.

BREED

Border Collie Mix

SEX

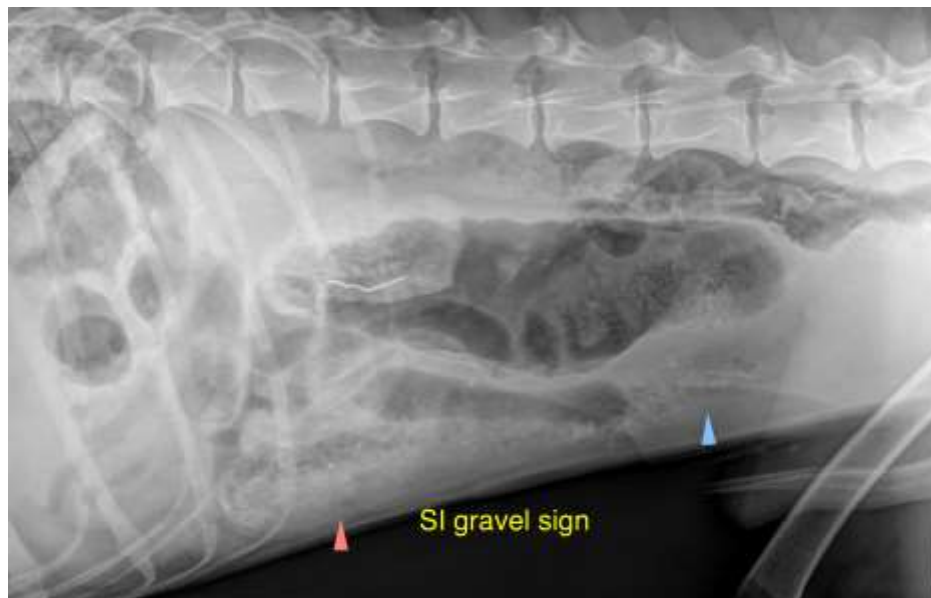Neutered Male

AGE

6 Years

INTERPRETED BY

Nele Eley, DVM
Dr. med. Vet. DipECVDI

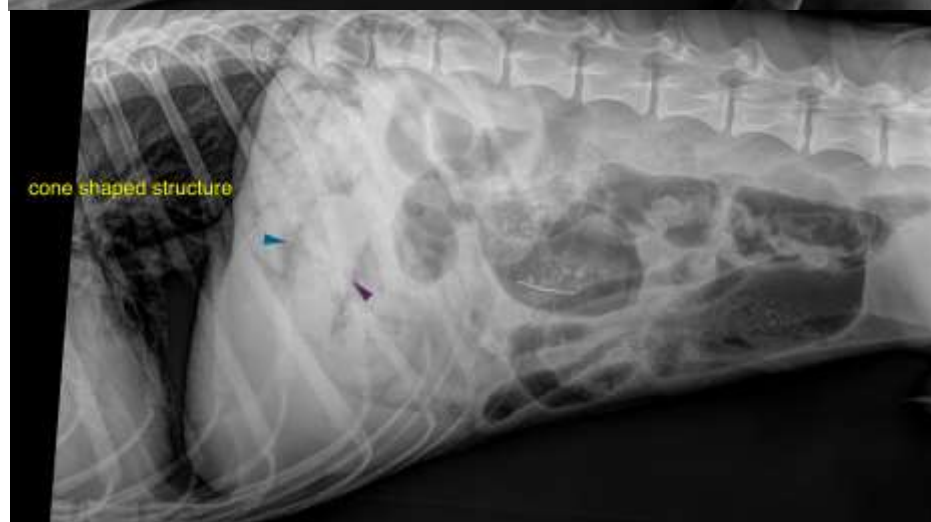


HOSPITAL NAME

Sierra Pet Clinic

REFERRING VET

Alejandro Garcia,
DVM



INVOICE

46943

DATE

8-10-21



PATIENT

HARDY BALLARD

The information and recommendations provided are based on the images presented by the referring veterinarian. No evaluation can be communicated regarding pathology that was not visible in the image/video clips provided.

SPECIES

Canine

Thank you for this referral. If the clinical or image interpretation does not parallel your findings or if I can be of any further assistance please contact me.

BREED

Border Collie Mix

Nele Eley, DVM, Dr. med. vet., DipECVDI
European Specialist in Veterinary Diagnostic Imaging, Cert. Radiology,
Senior lecturer University of Giessen, Germany, Veterinary Faculty, Department of Radiology
Nele.Eley@sonopath.com

SEX

Neutered Male

AGE

6 Years

INTERPRETED BY

Nele Eley, DVM
Dr. med. Vet. DipECVDI

HOSPITAL NAME

Sierra Pet Clinic

REFERRING VET

Alejandro Garcia,
DVM

INVOICE

46943

DATE

8-10-21