



PATIENT

Precious Rigby

SPECIES

Canine

BREED

Chihuahua

SEX

FI

AGE

12 Years, 8 Months

INTERPRETED BY

Nele Eley, DVM
Dr. med. Vet. DipECVDI

HOSPITAL NAME

Bridgwater
Veterinary Hospital
and Wellness Centre

REFERRING VET

Dr. Jennifer Beckwith

INVOICE

59609

DATE

8-1-23

PRESENTING CLINICAL SIGNS

Progressive ataxia and lameness RF leg. RDVM requested CT of cervical vertebrae/discs as well as neuromuscular system from neck to toes of RFL. Looking to r/o IVDD, nerve sheath tumor, etc. Chronic polycythemia, cholecystitis (stable). Grade 2/6 systolic heart murmur, stable, asymptomatic. During anesthesia for CT, patient became unstable, spO2 dropped to 72%, could not reverse it, decision made to abort the rest of the imaging so no contrast was given.

COMPUTED TOMOGRAPHIC STUDY OF THE CERVICAL SPINE & BILATERAL THORACIC LIMBS

Plain study available for review only. A post-contrast study could not be obtained owing to the instability of the patient under general anesthesia. Assessment of the soft tissues is limited.

COMPUTED TOMOGRAPHIC FINDINGS

Cervical Spine

The intervertebral disc spaces C5/6 and C6/7 are reduced in width. The collapse between C6 and C7 is almost complete. Sclerosis of the vertebral endplates is noted and a step formation on the floor of the vertebral canal with mild ventral deviation of C7. Moderate ventrally bridging spondylosis deformans is noted as well. There appears to be mild dorsal deviation and compression of the spinal cord accentuated to the right of the midline.

A mass is not overtly seen in the brachial plexus area.

Thoracic Limbs

The muscle volume of the right thoracic limb appears to be mildly reduced.

Mild osseous remodeling of the bicapital groove is seen in both shoulders.

The elbows present within age related normal limits.

Mild periarticular bone remodeling of the carpal joints and 2nd and 5th metacarpophalangeal joints is seen in both thoracic limbs.

COMPUTED TOMOGRAPHIC DIAGNOSIS

- Chronic intervertebral disc disease C6/7 with presumed compressive myelopathy.
- Intervertebral disc disease C5/6.
- Normal age related findings of the thoracic limbs.
- Atrophy of the right thoracic limb musculature.

INTERPRETATION OF THE FINDINGS & FURTHER RECOMMENDATIONS

The CT study reveals evidence of chronic intervertebral disc disease with presumed mild compressive myelopathy within the deep cervical spine between C6/7. The narrowing may be more pronounced on the right hand side. Irritation of the right spinal nerve root cannot be ruled out; however, the extent of the compression and effects on the spinal cord and nerve root cannot be determined accurately. An MRI could be considered for further assessment of potential spinal



PATIENT

cord and nerve root changes.

Precious Rigby

The intervertebral disc space narrowing C5/6 may represent uncomplicated degenerative disc disease or be associated with disc herniation. Again here, further definition by means of MRI (or CT myelogram) would be ideal.

SPECIES

Canine

A definitive cause of lameness was not identified in the study of the thoracic limbs. The osseous remodeling of the shoulders, carpi, and metacarpophalangeal joints is bilaterally symmetric and likely to be within age related normal limits.

BREED

Chihuahua

SEX

FI

AGE

12 Years, 8 Months

INTERPRETED BY

Nele Eley, DVM
Dr. med. Vet. DipECVDI

HOSPITAL NAME

Bridgwater
Veterinary Hospital
and Wellness Centre

REFERRING VET

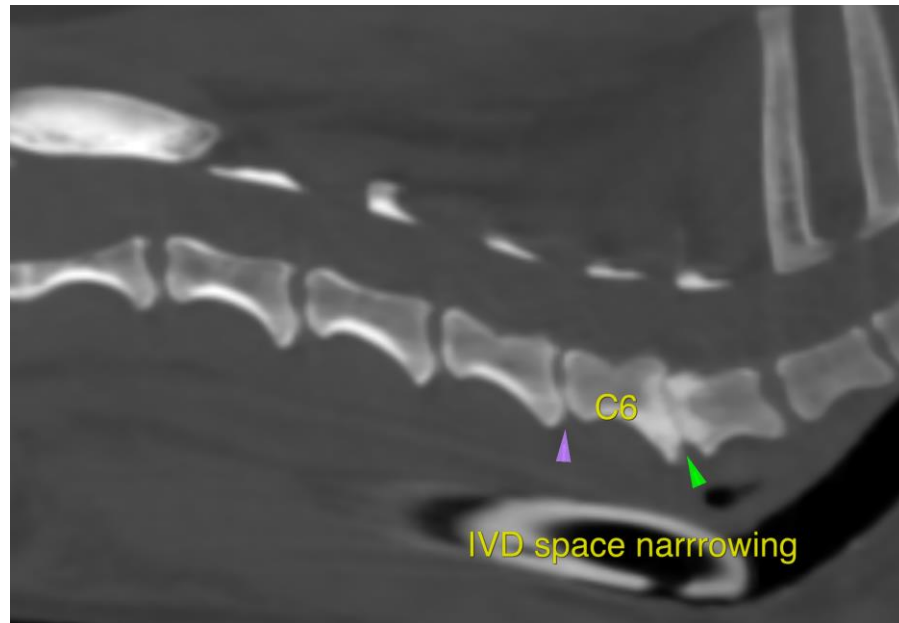
Dr. Jennifer Beckwith

INVOICE

59609

DATE

8-1-23



The information and recommendations provided are based on the images presented by the referring veterinarian/sonographer. No evaluation can be communicated regarding pathology that was not visible in the image/video clips provided.

Thank you for this referral. If the clinical or image interpretation does not parallel your findings or if I can be of any further assistance please contact me.

Nele Eley, DVM, Dr. med. vet., DipECVDI
European Specialist in Veterinary Diagnostic Imaging, Cert. Radiology,
Senior lecturer University of Giessen, Germany, Veterinary Faculty, Department of Radiology
info@sonopath.com