SonoPath Teleradiology

EDUCATIONAL TELECONSULTATION SERVICES™

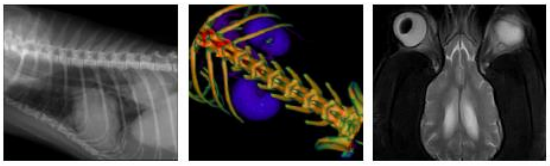

SonoPath.com
1-800-838-4268 info@sonopath.com

PATIENT

Murphy Dykes

SPECIES

Canine

BREED

Bulldog Mix

SEX

NM

AGE

2 Years, 7 Months

INTERPRETED BY

Nele Eley, DVM
Dr. med. Vet. DipECVDI

HOSPITAL NAME

DPC Veterinary Hospital

REFERRING VET

DMF

INVOICE

59235

DATE

7-8-23

PRESENTING CLINICAL SIGNS

Hx of hiatal hernia. Hx of ingesting mango pits

RADIOGRAPHIC STUDY OF THE ABDOMEN

Right/left lateral and ventrodorsal views of the abdomen totaling 4 images available for review.

RADIOGRAPHIC FINDINGS

Corkscrew tail breed with congenital malformation of the sacrococcygeal spine and caudal thoracic spine.

There is a sliding hiatal hernia with the lower esophageal sphincter being intermittently cranial to the diaphragmatic crura.

The stomach contains a mild amount of gas.

The small intestinal loops are evenly distributed throughout the mid abdomen and contain gas. No abnormal dilation or radiopaque foreign material is seen.

A moderate amount of fecal matter is seen within the colon.

The splenic tail is prominent.

RADIOGRAPHIC DIAGNOSIS

- Sliding hiatal hernia.
- No evidence of mechanical small intestinal ileus.
- Mild splenomegaly.
- Congenital vertebral malformations.

INTERPRETATION OF THE FINDINGS & FURTHER RECOMMENDATIONS

The radiographic study reveals a sliding hiatal hernia. The lower esophageal sphincter presents intermittent cranial displacement. At this time, there is no evidence of significant esophageal dilation. No esophageal foreign material is seen in the caudal thorax.

There is no radiographic evidence of small intestinal foreign material. The typical pattern for a mango pit is not seen even though fragmented pieces of which cannot be ruled out . There are no signs of full mechanical small intestinal obstruction.

The vomiting may be due to the hiatal hernia or functional ileus. Mechanical ileus is not considered likely based on the radiographic findings. However, further definition by means of abdominal ultrasound or repeat radiographs could be considered in case of persisting or deteriorating clinical signs.

The mild splenomegaly may be a normal anatomic variant. Extramedullary hematopoiesis, splenitis, lymphoid hyperplasia, and diffuse infiltrative disease are potential but less likely differential diagnoses.

SonoPath Teleradiology

EDUCATIONAL TELECONSULTATION SERVICES™

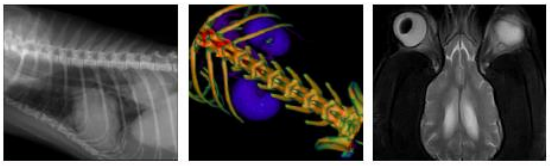

SonoPath.com
1-800-838-4268 info@sonopath.com

PATIENT

Murphy Dykes

SPECIES

Canine

BREED

Bulldog Mix

SEX

NM

AGE

2 Years, 7 Months

INTERPRETED BY

Nele Eley, DVM
Dr. med. Vet. DipECVDI

HOSPITAL NAME

DPC Veterinary Hospital

REFERRING VET

DMF

INVOICE

59235

DATE

7-8-23

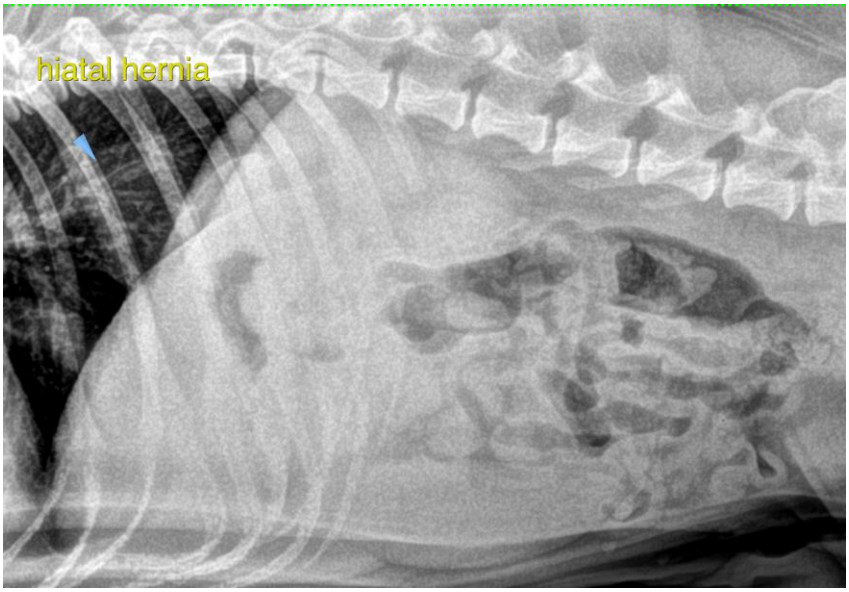

The information and recommendations provided are based on the images presented by the referring veterinarian/sonographer. No evaluation can be communicated regarding pathology that was not visible in the image/video clips provided.

Thank you for this referral. If the clinical or image interpretation does not parallel your findings or if I can be of any further assistance please contact me.

Nele Eley, DVM, Dr. med. vet., DipECVDI
European Specialist in Veterinary Diagnostic Imaging, Cert. Radiology,
Senior lecturer University of Giessen, Germany, Veterinary Faculty, Department of Radiology
info@sonopath.com