



PATIENT

Ellie Brown

PRESENTING CLINICAL SIGNS

Elevated ALT and BUN, Bile Acids significantly elevated: Pre 206.2, Post 274.6. Highly suspect congenital PSS. Liver is subjectively small on ultrasound.

SPECIES

Canine

COMPUTED TOMOGRAPHIC STUDY OF THE ABDOMEN

Plain and post contrast studies available for review.

BREED

Shih Tzu

COMPUTED TOMOGRAPHIC FINDINGS

A single extrahepatic portosystemic shunt emerging from the right gastric vein is seen. The shunt measures a maximum of 6mm in diameter and loops medially as well as dorsally to feed into the caudal vena cava from the lefthand side level with the cranial pole of the right kidney. Portal vein diameter decreases abruptly cranial to the shunt origin.

SEX

FS

The liver is small in size. Intrahepatic portal vein branching appears to be reduced. The gallbladder is moderately to severely distended with uniformly fluid attenuating content.

No evidence of renal or urinary bladder calculi is seen.

AGE

10 Months

COMPUTED TOMOGRAPHIC DIAGNOSIS

- Single congenital extrahepatic portosystemic shunt of the right gastric vein type.
- Microhepatica.

INTERPRETED BY

Nele Eley, DVM
Dr. med. Vet. DipECVDI

INTERPRETATION OF THE FINDINGS & FURTHER RECOMMENDATIONS

The CT study confirms presence of a portosystemic vascular bypass. A congenital extrahepatic right gastric vein shunt is identified. Consider shunt closure by means of a slowly attenuating technique as well as dietetic and medical management.

HOSPITAL NAME

Mountain West
Veterinary Hospital

REFERRING VET

Melanie Thompson

INVOICE

52725

DATE

7-7-22



PATIENT

Ellie Brown

SPECIES

Canine

BREED

Shih Tzu

SEX

FS

AGE

10 Months

INTERPRETED BY

Nele Eley, DVM
Dr. med. Vet. DipECVDI

HOSPITAL NAME

Mountain West
Veterinary Hospital

REFERRING VET

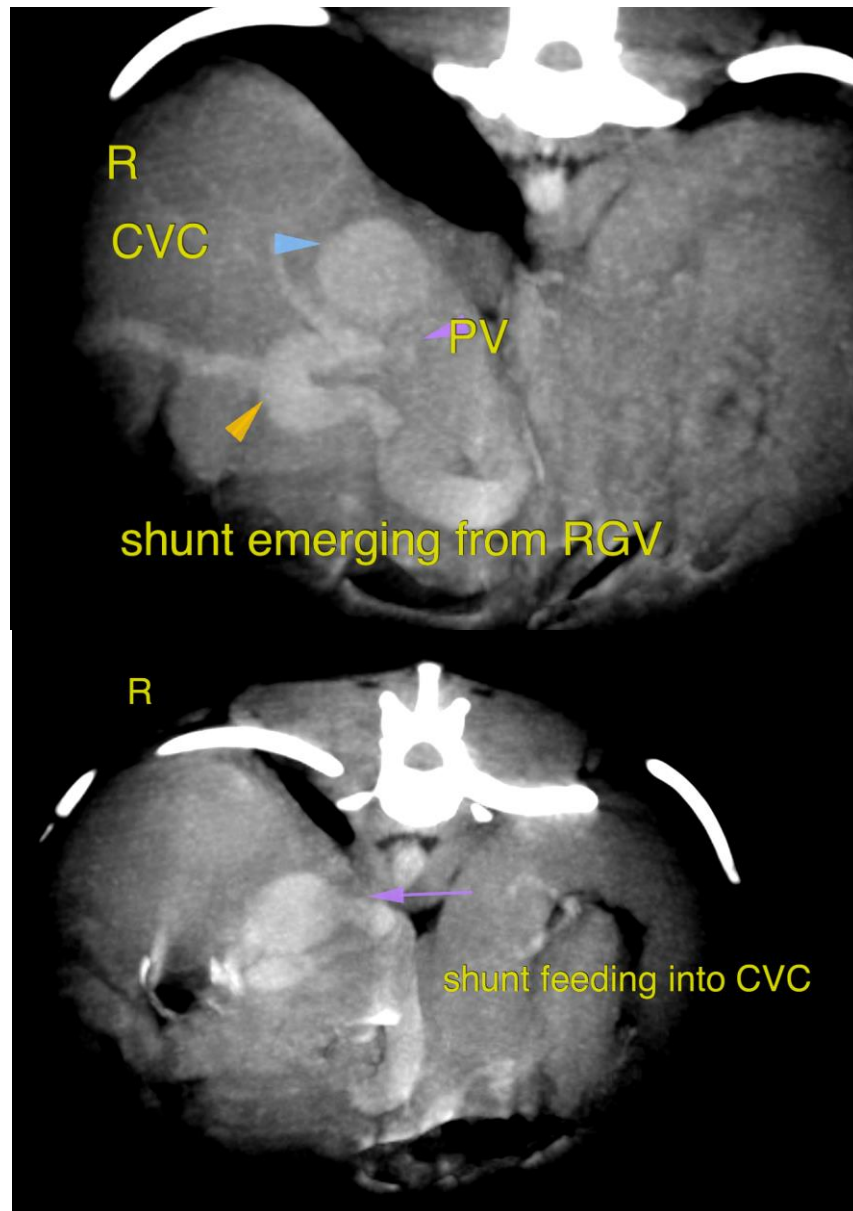
Melanie Thompson

INVOICE

52725

DATE

7-7-22





PATIENT

Ellie Brown

The information and recommendations provided are based on the images presented by the referring veterinarian/sonographer. No evaluation can be communicated regarding pathology that was not visible in the image/video clips provided.

Thank you for this referral. If the clinical or image interpretation does not parallel your findings or if I can be of any further assistance please contact me.

SPECIES

Canine

Nele Eley, DVM, Dr. med. vet., DipECVDI
European Specialist in Veterinary Diagnostic Imaging, Cert. Radiology,
Senior lecturer University of Giessen, Germany, Veterinary Faculty, Department of Radiology
Nele.Eley@sonopath.com

BREED

Shih Tzu

SEX

FS

AGE

10 Months

INTERPRETED BY

Nele Eley, DVM
Dr. med. Vet. DipECVDI

HOSPITAL NAME

Mountain West
Veterinary Hospital

REFERRING VET

Melanie Thompson

INVOICE

52725

DATE

7-7-22