



PATIENT

Biggie O'Connor

PRESENTING CLINICAL SIGNS

Approx 12yr old male chihuahua presented for a large lump on the anus that developed over the past 4 days when the owner was out of town. O admits that he has had some episodes of constipation. Daughter feels that it has decreased in size yesterday. Pet has minimal vet hx(rv only)

SPECIES

Canine

Abnormal PE/Chem/CBC/UA Results: Physical Examination Key -- (N= Normal, A= Abnormal)
 Hydration: Appropriately hydrated Mentation: BAR EENT: No nasal discharge; nuclear sclerotic OU; clean no debris AU; No cough on tracheal palpation. Oral Cavity: no teeth remaining Lymph Nodes: Symmetrical, no changes in size, shape, consistency Skin: Good hair coat, no signs of ectoparasites. See "Uro/Perineum" CV/Respiratory: No murmur or crackles/wheezing auscultated. Synchronous pulses, normal rate. Normal bronchovesicular sounds. Abd/GI: Soft non painful abdomen Uro/Perineum: Large soft mass just left of anus and tail - suspect perineal hernia Musculoskeletal: Ambulatory x4, no lameness noted. No pain on palpation of limbs. BCS 5/9 Neurological: Appropriate

BREED

Chihuahua

SEX

Intact Male

RADIOGRAPHIC STUDY OF THE ABDOMEN

Lateral and ventrodorsal views totaling 2 images available for review.

AGE

11 Years, 10 Months

RADIOGRAPHIC FINDINGS

An approximately 3.0 cm sized soft tissue swelling is seen in the perineal region to the left of the base of the tail. No significant mass effect onto the colon and rectum is seen.

INTERPRETED BY

Nele Eley, DVM
 Dr. med. Vet. DipECVDI

No evidence of constipation of the colon is seen. The colon is empty.

The small intestinal loops contain gas and are nondilated and evenly distributed throughout the mid abdomen.

HOSPITAL NAME

DPC Veterinary
 Hospital

The stomach is postprandial.

The prostate and urinary bladder cannot be delineated in the abdominal cavity.

There is no evidence of sublumbar lymphadenomegaly.

REFERRING VET

Dr. White

Bilateral medial patella luxation is seen and appears to be stationary between the lateral and ventrodorsal images.

RADIOGRAPHIC DIAGNOSIS

- Left sided perineal soft tissue mass effect.
- Prostate and urinary bladder not seen in the abdomen.
- No evidence of constipation.
- Bilateral medial patella luxation and stifle osteoarthritis.

INVOICE

59215

DATE

7-6-23

INTERPRETATION OF THE FINDINGS & FURTHER RECOMMENDATIONS

The patient does not appear to be constipated at this time; however, tenesmus may be present clinically. The position of the mass effect is compatible with a perineal hernia. Other mass of course cannot be ruled out based on the radiographs alone and clinical correlation is required.



PATIENT

Biggie O'Connor

The prostate and urinary bladder are not seen in the abdomen. The urinary bladder may be empty. Prostate and urinary bladder may be mobile and caudally displaced which is a common cooccurrence with perineal hernia and may represent an emergency when combined with retroflexion of the urinary bladder and lower urinary tract obstruction (which does not appear to be the case here). Prostatic pathology should be ruled out by means of clinical palpation with eventual ultrasound and sampling as underlying cause of tenesmus.

SPECIES

Canine

BREED

Chihuahua

SEX

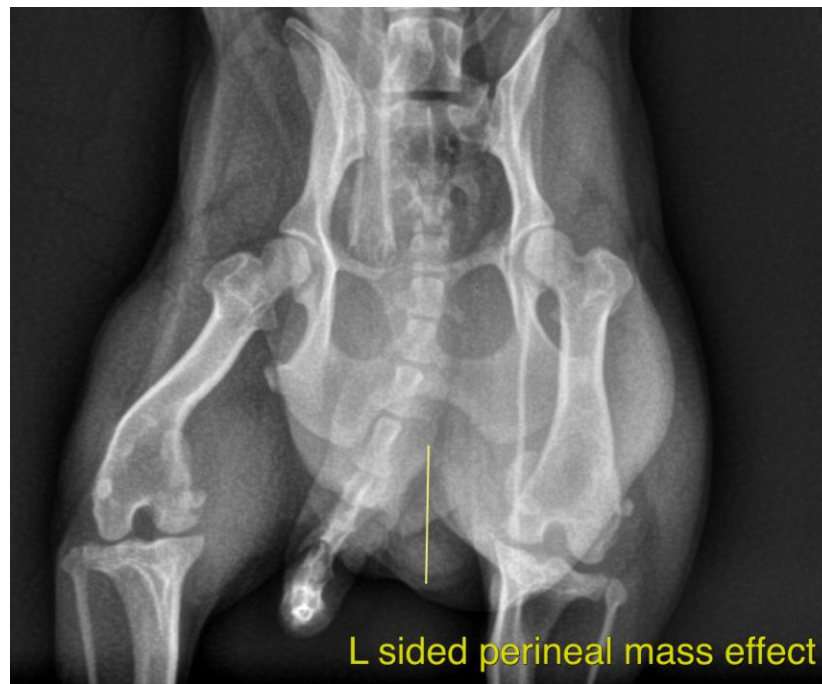
Intact Male

AGE

11 Years, 10 Months

INTERPRETED BY

Nele Eley, DVM
Dr. med. Vet. DipECVDI



HOSPITAL NAME

DPC Veterinary
Hospital

The information and recommendations provided are based on the images presented by the referring veterinarian/sonographer. No evaluation can be communicated regarding pathology that was not visible in the image/video clips provided.

REFERRING VET

Dr. White

Thank you for this referral. If the clinical or image interpretation does not parallel your findings or if I can be of any further assistance please contact me.

Nele Eley, DVM, Dr. med. vet., DipECVDI
European Specialist in Veterinary Diagnostic Imaging, Cert. Radiology,
Senior lecturer University of Giessen, Germany, Veterinary Faculty, Department of Radiology
info@sonopath.com

INVOICE

59215

DATE

7-6-23