

**PATIENT**

Lady Rowan

**PRESENTING CLINICAL SIGNS**

Limping RR for 1 month  
Abnormal PE/Chem/CBC/UA Results: Exam: R knee flexion pain; R cranial drawer

**SPECIES**

Canine

**ULTRASONOGRAPHIC FINDINGS****Right Stifle**

Moderate effusion and synovial swelling of the right stifle joint are seen. There are moderate osteophytes at the visible periarticular margins. The cranial cruciate ligament presents continuous with slightly ill-defined margins and generalized swelling. The medial meniscus is in situ and of uniform echogenicity. The meniscal margins are smoothly delineated.

**BREED**American Cocker  
Spaniel**Left Stifle**

Mild effusion and mild synovial swelling as well as mild periarticular osteophytes are seen. The cranial cruciate ligament presents continuous, well delineated, and of normal thickness. The medial meniscus is in situ, smoothly delineated, and presents uniform internal echoarchitecture.

**SEX**

FS

**ULTRASONOGRAPHIC DIAGNOSIS**

- Moderate right stifle osteoarthritis with cranial cruciate ligament injury.
- Mild left stifle osteoarthritis with no evidence of cruciate ligament or meniscal injury.

**AGE**

9.5 Years

**INTERPRETATION OF THE FINDINGS & FURTHER RECOMMENDATIONS**

The ultrasonographic findings support the presence of partial rupture of the right cranial cruciate ligament. Emerging/partial fiber disruption is assumed and may be associated with biomechanical failure, which can lead to further articular damage such as meniscal injury. Hence, surgical intervention should be considered for the right stifle.

**INTERPRETED BY**Nele Eley, DVM  
Dr. med. Vet. DipECVDI**HOSPITAL NAME**Colorado Animal  
Specialty &  
Emergency**REFERRING VET**

James Gaynor

**INVOICE**

52721

**DATE**

7-6-22



**PATIENT**

Lady Rowan

**SPECIES**

Canine

**BREED**

American Cocker  
Spaniel

**SEX**

FS

**AGE**

9.5 Years

**INTERPRETED BY**

Nele Eley, DVM  
Dr. med. Vet. DipECVDI

**HOSPITAL NAME**

Colorado Animal  
Specialty &  
Emergency

**REFERRING VET**

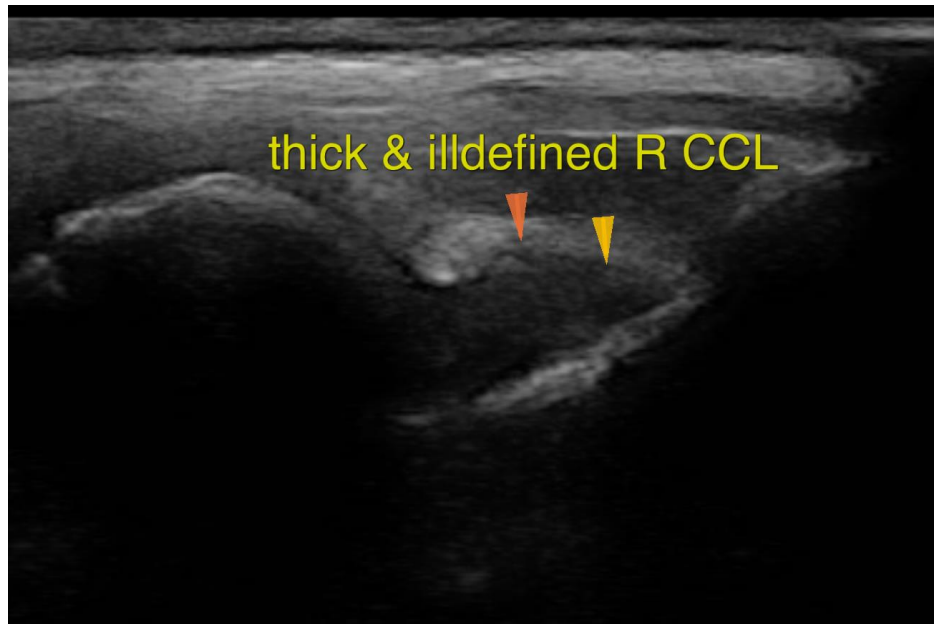
James Gaynor

**INVOICE**

52721

**DATE**

7-6-22



The information and recommendations provided are based on the images presented by the referring veterinarian/sonographer. No evaluation can be communicated regarding pathology that was not visible in the image/video clips provided.

Thank you for this referral. If the clinical or image interpretation does not parallel your findings or if I can be of any further assistance please contact me.

**Nele Eley**, DVM, Dr. med. vet., DipECVDI  
European Specialist in Veterinary Diagnostic Imaging, Cert. Radiology,  
Senior lecturer University of Giessen, Germany, Veterinary Faculty, Department of Radiology  
Nele.Eley@sonopath.com