



PATIENT PRESENTING CLINICAL SIGNS

Willy Hahn slowing down, having difficulty doing stairs, lethargic, changes have been gradual
 Abnormal PE/Chem/CBC/UA Results: CBC and chemistry WNL

SPECIES RADIOGRAPHIC STUDY OF THE NECK, THORAX, ABDOMEN, SHOULDERS, ELBOWS, FRONT PAWS, & BILATERAL STIFLES

Canine 11 images are available for review.

BREED RADIOGRAPHIC FINDINGS

Cockapoo **Spine**

Number, alignment, and general anatomy of the cervical, thoracic, and lumbar vertebrae present within normal limits.

SEX

MN

The craniocervical junction presents within normal limits.

Mineralization of the C2/3 intervertebral disc is seen. The disc appears to be in situ.

AGE

11 Years

Neck & Thorax

Course and width of the trachea are considered within normal limits.

INTERPRETED BY

Nele Eley, DVM
 Dr. med. Vet. DipECVDI

The degree of pulmonary inflation is moderate. A mild generalized bronchointerstitial lung pattern is noted and considered within age related normal limits.

There is no evidence of abnormal mediastinal widening.

HOSPITAL NAME

Balmy Beach Pet Hospital

The cardiac silhouette presents within normal limits. No specific chamber enlargement is noted. The vertebral heart score is 10.

Abdomen

The abdominal serosal detail is maintained.

REFERRING VET

Dr. Singh

The liver and spleen present within expected limits.

A mild amount of gravel appears to be present within the stomach.

Turgid appearance of the small intestine is seen with no evidence of abnormal dilation.

INVOICE

59204

The colon and cecum present within expected limits.

The left kidney presents within normal limits. Assessment of the right kidney is obscured owing to superimposition with the gastrointestinal tract.

DATE

7-5-23

The urinary bladder presents within normal limits.

The coxofemoral joints present within normal limits.



PATIENT **Front Limbs**

Willy Hahn The shoulders and elbows present within normal limits.
 The muscle volume of the thoracic limbs appears to be adequate and symmetric.

SPECIES
 Canine The carpal joints present within normal limits.

Moderate osteoarthritic changes of the metacarpophalangeal joints of the 2nd digits are seen within both front paws.

BREED **Hind Limbs**

Cockapoo The right and left stifle and tarsal joints present within normal limits.

SEX **RADIOGRAPHIC DIAGNOSIS**

- MN
- Mild small intestinal maldigestion pattern
 - Radiographic absence of the right kidney – otherwise normal radiographic presentation of the abdomen.
 - Normal age related presentation of the thorax.
 - Chondroid degeneration of the C2/3 intervertebral disc -otherwise normal radiographic presentation of the spine.
 - Normal radiographic presentation of the coxofemoral, stifle, and tarsal joints.
 - Normal radiographic presentation of the shoulder and elbow joints.
 - Moderate bilateral metacarpophalangeal joint osteoarthritis in the 2nd digits.

AGE
 11 Years

INTERPRETED BY

Nele Eley, DVM
 Dr. med. Vet. DipECVDI

INTERPRETATION OF THE FINDINGS & FURTHER RECOMMENDATIONS

The radiographic presentation of the thorax is within age related normal limits. No evidence of bronchopulmonary or cardiovascular pathology is seen radiographically.

HOSPITAL NAME

Balmy Beach Pet Hospital

The small intestinal maldigestion pattern and mild gastric gravel sign may be a consequence of functional ileus/ disturbed motility with gastroenteropathy. This may however also be an incidental finding. Clinical correlation is required. Further definition by means of abdominal ultrasound could be considered in case of coexisting pertinent clinical signs.

REFERRING VET

Dr. Singh

The radiographic presentation of the spine was within normal limits except for presence of mineralization of the C2/3 intervertebral disc. The disc appears to be in situ.

INVOICE

59204

Note the presence of moderate osteoarthritic changes of the metacarpophalangeal joints in the 2nd digit in both front paws.

The remainder of the joints in the front and hind limbs present within normal limits.

DATE

7-5-23



PATIENT

Willy Hahn

SPECIES

Canine

BREED

Cockapoo

SEX

MN

AGE

11 Years

INTERPRETED BY

Nele Eley, DVM
Dr. med. Vet. DipECVDI

HOSPITAL NAME

Balmy Beach Pet
Hospital

REFERRING VET

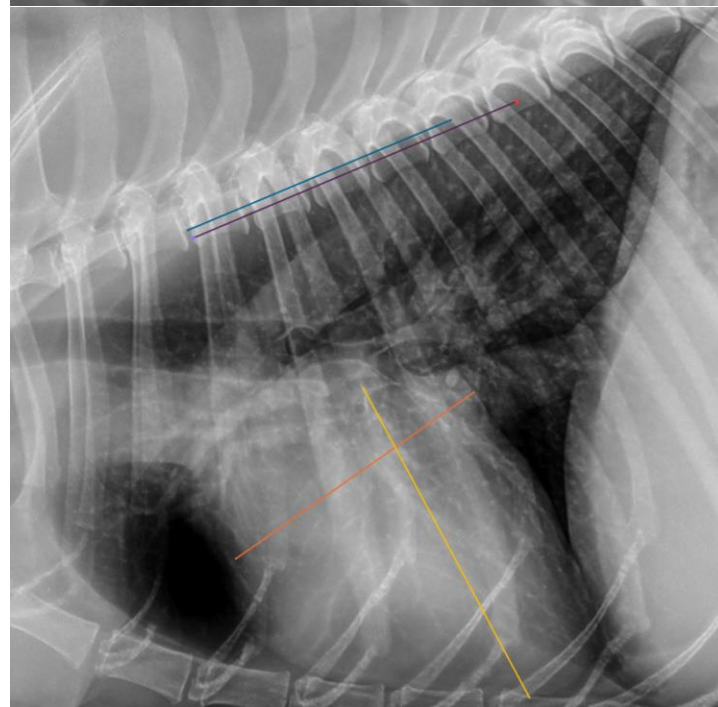
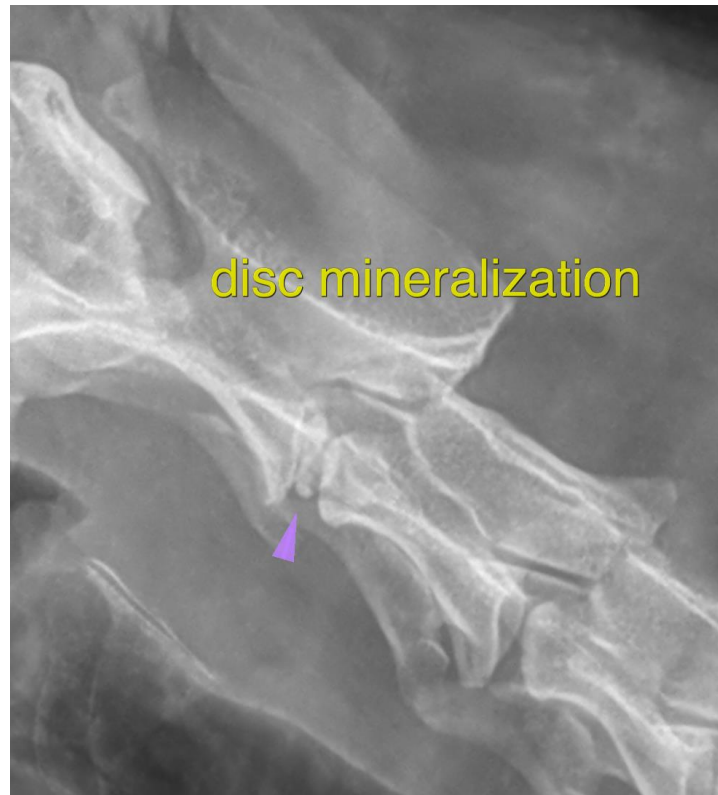Dr. Singh

INVOICE

59204

DATE

7-5-23





PATIENT

Willy Hahn

The information and recommendations provided are based on the images presented by the referring veterinarian/sonographer. No evaluation can be communicated regarding pathology that was not visible in the image/video clips provided.

Thank you for this referral. If the clinical or image interpretation does not parallel your findings or if I can be of any further assistance please contact me.

SPECIES

Canine

Nele Eley, DVM, Dr. med. vet., DipECVDI
European Specialist in Veterinary Diagnostic Imaging, Cert. Radiology,
Senior lecturer University of Giessen, Germany, Veterinary Faculty, Department of Radiology
info@sonopath.com

BREED

Cockapoo

SEX

MN

AGE

11 Years

INTERPRETED BY

Nele Eley, DVM
Dr. med. Vet. DipECVDI

HOSPITAL NAME

Balmy Beach Pet
Hospital

REFERRING VET

Dr. Singh

INVOICE

59204

DATE

7-5-23