



**PATIENT**

Chaos Hindman

**PRESENTING CLINICAL SIGNS**

Hurt leg on July 1st jumping off porch. Has been on prednisone for couple weeks for pododermatitis. Added gabapentin and is still limping.  
 Abnormal PE/Chem/CBC/UA Results: Lyme Negative; Sedated exam shows minimal/mild drawer. Some stifle thickening present .

**SPECIES**

Canine

**ULTRASONOGRAPHIC FINDINGS**

**Left Stifle**

A mild amount of anechoic effusion is seen within the supra- and infra- patellar recesses of the left stifle joint. Mild periarticular bone remodeling is noted. There is moderate swelling of the synovium. The distal attachment of the cranial cruciate ligament is surrounded by a hypoechoic halo. Partial fiber disruption is noted. A thicker continuous portion of the cruciate ligament appears to be present and maintained. The medial meniscus is in situ. No evidence of meniscal damage is seen.

**BREED**

Golden Doodle

**SEX**

Female Spayed

**ULTRASONOGRAPHIC DIAGNOSIS**

- Suspect partial rupture of the left cranial cruciate ligament with mild to moderate left stifle osteoarthritis.

**AGE**

6 Years

**INTERPRETATION OF THE FINDINGS & FURTHER RECOMMENDATIONS**

The ultrasonographic findings suggest presence of partial rupture of the left cranial cruciate ligament. Progressive biomechanical failure is assumed, and surgical intervention should be considered in order to prevent further damage to the articular structures such as the menisci.

**INTERPRETED BY**

Nele Eley, DVM  
 Dr. med. Vet. DipECVDI

**HOSPITAL NAME**

Franklin Animal Clinic  
 Inc.

**REFERRING VET**

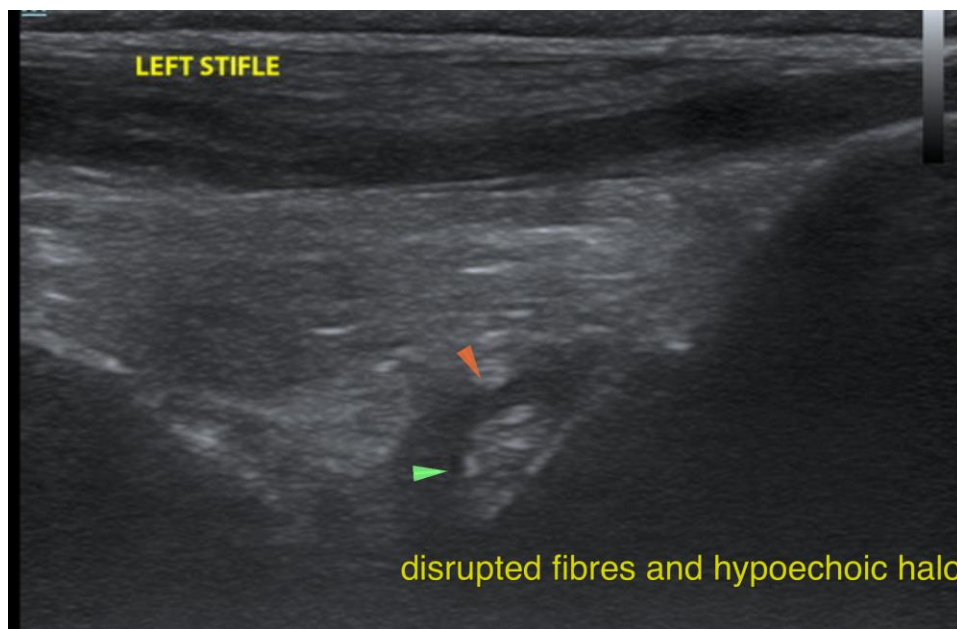
Sam Doverspike

**INVOICE**

52707

**DATE**

7-5-22





**PATIENT**

Chaos Hindman

The information and recommendations provided are based on the images presented by the referring veterinarian/sonographer. No evaluation can be communicated regarding pathology that was not visible in the image/video clips provided.

Thank you for this referral. If the clinical or image interpretation does not parallel your findings or if I can be of any further assistance please contact me.

**SPECIES**

Canine

**Nele Eley**, DVM, Dr. med. vet., DipECVDI  
European Specialist in Veterinary Diagnostic Imaging, Cert. Radiology,  
Senior lecturer University of Giessen, Germany, Veterinary Faculty, Department of Radiology  
Nele.Eley@sonopath.com

**BREED**

Golden Doodle

**SEX**

Female Spayed

**AGE**

6 Years

**INTERPRETED BY**

Nele Eley, DVM  
Dr. med. Vet. DipECVDI

**HOSPITAL NAME**

Franklin Animal Clinic  
Inc.

**REFERRING VET**

Sam Doverspike

**INVOICE**

52707

**DATE**

7-5-22