



PATIENT

Zoe Ly

PRESENTING CLINICAL SIGNS

History Patient has a week history of right hind limb dragging and walking difficulty EDDU otherwise normal Exam Chest ausc NAD MM pink. CRT<2 Neurological exam - dragging RHL when walking, proprioception normal, withdrawal and patella reflex wnl. Assessment - Underling sciatic nerve disease or lumbar disease - IVDD, inflammatory, infectious, neoplastic disease Discussed CT scan of the lumbar region and RHL + myelogram and contrast, owner aware patient is under anaesthesia Butorphanol 0.4ml IV, ACP 0.2ml IV Alfaxalone slow IV Intubated Cuff inflated Iso and oxygen maintenance Performed CT with myelogram of the lumbar spine, CT of the RHL and lumbar musculature (native and contrast) Myelogram contrast - 4mls iohexol IV contrast - 36ml IV in total Regurgitated on recovery

SPECIES

Canine

BREED

Staffy

COMPUTED TOMOGRAPHIC STUDY OF THE HIND LIMBS & LUMBAR SPINE

Myelogram of the lumbar spine with lumbar puncture in soft tissue and bone windows available for review. Plain and post IV contrast studies of the hind limbs in soft tissue and bone windows available for review.

SEX

F

COMPUTED TOMOGRAPHIC FINDINGS

Number, alignment, and general anatomy of the lumbar vertebrae present within normal limits.

AGE

5 Years

Minimal protrusion of the annulus fibrosis of the intervertebral discs T12/13 and L7/S1 is seen with no evidence of spinal cord compression or cauda equina compression. There is no evidence of neuroforaminal stenosis.

INTERPRETED BY

Nele Eley, DVM
Dr. med. Vet. DipECVDI

The iliopsoas, gracilis, and semitendinosus muscles present within normal limits.

The gluteus muscles present within normal limits.

HOSPITAL NAME

Colyton Veterinary
Hospital

The sciatic nerves are within normal limits from the exit zone of the L6/7 neuroforamina up to the proximal hind limbs.

No significant muscle atrophy is seen.

The gastrocnemius muscles and stifle joints present within normal limits.

REFERRING VET

Dalton Nguyen

The popliteal lymph nodes present within normal limits.

The bilateral tarsal joints present within normal limits.

The muscle volume of both hind limbs is adequate and symmetric.

INVOICE

59154

The bilateral coxofemoral joints present within normal limits with no evidence of dysplasia or osteoarthritis.

The sacroiliac joints present within normal limits.

DATE

7-4-23



PATIENT **COMPUTED TOMOGRAPHIC DIAGNOSIS**

- Zoe Ly
- Minimal noncompressive protrusions T12/13 and L7/S1.
 - Normal CT findings of the sciatic nerves and hind limbs.

SPECIES **INTERPRETATION OF THE FINDINGS & FURTHER RECOMMENDATIONS**

Canine
The CT study is negative for structural lesions within the musculature, bones, or joints of the hind limbs. The lumbar spine presents largely within normal limits.

BREED
Staffy
Noncompressive acute nucleus pulposus extrusion and ischemic myelopathy such as fibrocartilaginous embolism remain a potential and could correlate with the patient’s clinical signs. The clinical findings appear to be less typical for inflammatory/infectious and degenerative spinal disease. Infiltrative disease can never be ruled out entirely but is also not considered a likely potential in this case.

SEX
F
MRI and CSF analysis could be considered further diagnostic options in case the clinical signs of the patient persist or deteriorate.

AGE

5 Years

INTERPRETED BY

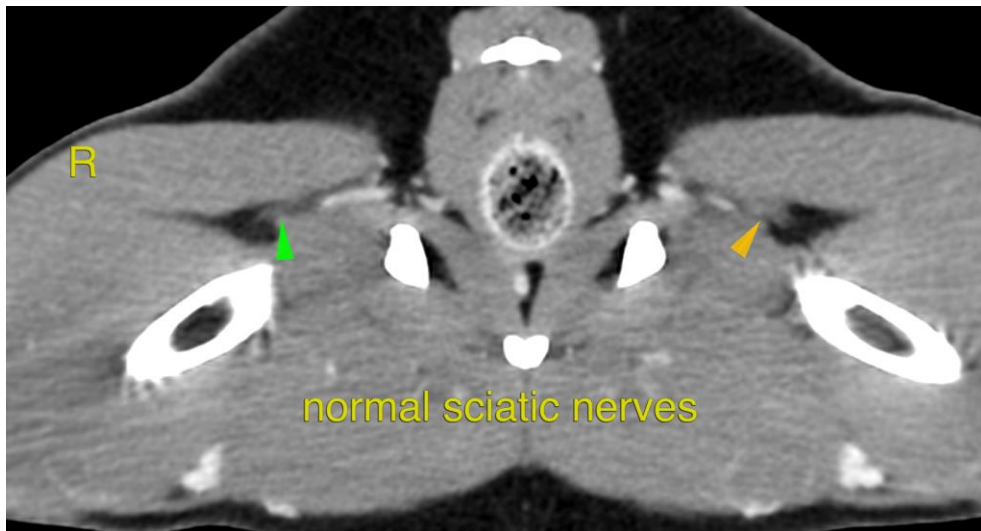
Nele Eley, DVM
Dr. med. Vet. DipECVDI

HOSPITAL NAME

Colyton Veterinary
Hospital

REFERRING VET

Dalton Nguyen



The information and recommendations provided are based on the images presented by the referring veterinarian/sonographer. No evaluation can be communicated regarding pathology that was not visible in the image/video clips provided.

INVOICE

59154

DATE

7-4-23

Thank you for this referral. If the clinical or image interpretation does not parallel your findings or if I can be of any further assistance please contact me.

Nele Eley, DVM, Dr. med. vet., DipECVDI
European Specialist in Veterinary Diagnostic Imaging, Cert. Radiology,
Senior lecturer University of Giessen, Germany, Veterinary Faculty, Department of Radiology
info@sonopath.com