



PATIENT PRESENTING CLINICAL SIGNS

PATIENT
Bruiser Hoskins

SPECIES
Canine

BREED
Belgian Malinois

SEX
NM

AGE
1 Year

Reason for today's visit: P came in today for a swollen face/ jaw.... O thought it was an ear infection, when it first happened about 2-3wks ago. O took P to RDVM 2 time 1st time was for some shots and the 2nd time was for the steroids. O also informed us that RDVM thought it might have been an abscess but the swelling came back. O was prescribed prednisone and another one (in the records) for the swelling to go down. O says that the Rx worked for a while but after the swelling was gone it would return the next day O says looking worse. O says that the swelling starts under the eye and around the nose and jaw, than slowly the swelling will go down to the neck. to me the neck swelling feels as if it is squishy. O says the swelling started up again this morning, & she called RDVM but they referred O to us due to being stumped on what is happening with P.O says that P is only in pain when the swelling starts. but seems to be fine when the swelling goes down to the neck. ED: eating a lot more than usual O thinks its due to the Rx from the RDVM... drinking more water than normal now days too. PP: O says Peeing is normal but poop is a little runny could be due to the water intake RDVM told O to put rice in the food to help with the runny stool. Previous medical conditions diagnosed: Is pet on medications (list): steroid Prednisone 20mg half a pill a dag Is pet current on vaccines (list): due at the end of this month. O was told by RDVM to control this issue first. Current heartworm/ flea & tick medication: bravecto/ and once a year shot for the hw (got the hw shot a few weeks ago) Current diet: purina pro/ soft half can in the morning and night dry food is free fed throughout out the day , mixed with freeze dry dog food, called Chewie wild red. treats: natural smart bone brand, PPL food once in a while O stays away from chicken O was told it could be bad for P. Abnormal PE/Chem/CBC/UA Results: WBC 27.13, Neutrophils 21.86, Monocytes 2.1, PDW 8.7, BUN 31, ALT 193

INTERPRETED BY COMPUTED TOMOGRAPHIC STUDY OF THE HEAD & NECK

Nele Eley, DVM
Dr. med. Vet. DipECVDI

Plain and post contrast studies available for review.

COMPUTED TOMOGRAPHIC FINDINGS

HOSPITAL NAME
Neel Veterinary Hospital

An elongated cavitory lesion of 4 cm height, 1 cm width, and 12 cm length is seen parallel to the left lateral masseter muscle. Capsular peripheral thickening with increased rim enhancement and extensive perilesional soft tissue swelling with fat stranding are seen. The tubular cavity appears to connect with the enlarged left parotid salivary gland and ends level with the 4th premolar. The left parotid gland presents slightly increased contrast enhancement.

REFERRING VET
Deepan Kishore, DVM,MS, DABVP

The left parotid, left submandibular, and left retropharyngeal lymph nodes present mild to moderate symmetric enlargement with peripheral fat stranding and soft tissue swelling.

COMPUTED TOMOGRAPHIC DIAGNOSIS

- Suspect sialadenitis and ductilitis of the left parotid salivary gland with extensive peripheral cellulitis and regional lymphadenitis.

INVOICE

59153

INTERPRETATION OF THE FINDINGS & FURTHER RECOMMENDATIONS

DATE

7-4-23

The CT findings are highly suggestive for sialadenitis of the left parotid salivary gland with dilation and severe inflammation of the parotid duct with extensive peripheral cellulitis and regional lymphadenitis. Foreign material or sialolithiasis are not seen. Migrating foreign material and abscess formation are a potential but by far less likely differential diagnosis.



PATIENT

Bruiser Hoskins

SPECIES

Canine

BREED

Belgian Malinois

SEX

NM

AGE

1 Year

INTERPRETED BY

Nele Eley, DVM
Dr. med. Vet. DipECVDI

HOSPITAL NAME

Neel Veterinary
Hospital

REFERRING VET

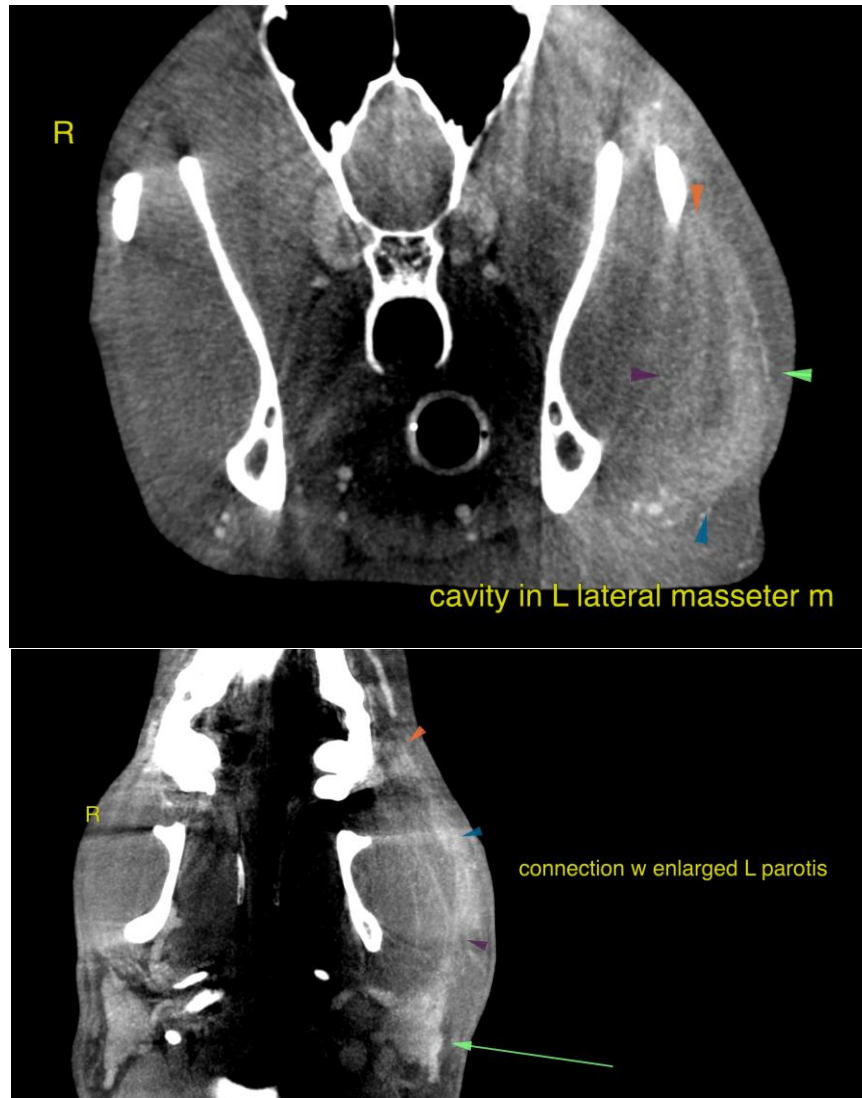
Deepan Kishore,
DVM,MS, DABVP

INVOICE

59153

DATE

7-4-23



The information and recommendations provided are based on the images presented by the referring veterinarian/sonographer. No evaluation can be communicated regarding pathology that was not visible in the image/video clips provided.

Thank you for this referral. If the clinical or image interpretation does not parallel your findings or if I can be of any further assistance please contact me.

Nele Eley, DVM, Dr. med. vet., DipECVDI
European Specialist in Veterinary Diagnostic Imaging, Cert. Radiology,
Senior lecturer University of Giessen, Germany, Veterinary Faculty, Department of Radiology
info@sonopath.com