



PATIENT PRESENTING CLINICAL SIGNS

PATIENT Phoebe Farnell
SPECIES Canine
BREED Airdale
SEX FS
AGE 3 Years, 7 Months

PRESENTING CLINICAL SIGNS Limping has been limping on the right front leg for over two months or more. Worse after exercise, limps upon rising. Stiff and sore. Plays hard with the other dog. Has decreased muscle mass over the right scapula. Dog reacts with digit palpation but may just be the dogs behavior. Site of pain not determined with exam.

ULTRASONOGRAPHIC FINDINGS

Right Shoulder

The right supraspinatus tendon measures 5mm in average maximum thickness. There is no evidence of tendinous remodeling. The attachment to the greater humeral tubercle is smooth. No evidence of biceps impingement is noted. The biceps tendon presents no evidence of echoarchitectural changes and is smoothly delineated. A mild amount of anechoic effusion is seen within the bicipital tendon sheath. There is mild swelling of the tendon sheath's synovium and mild smoothly delineated exostosis within the bicipital groove. The supraspinatus and infraspinatus muscles present generalized loss of their volume with mild diffuse increase in echogenicity. The echoarchitecture of the muscles is maintained. The fascial planes are smooth and thin.

INTERPRETED BY

Nele Eley, DVM
 Dr. med. Vet. DipECVCI

ULTRASONOGRAPHIC DIAGNOSIS

- Mild chronic right biceps tenosynovitis.
- Myopathy of the right supra- and infra-spinatus muscles compatible with atrophy and fatty replacement.

HOSPITAL NAME

Westview Veterinary Hospital

INTERPRETATION OF THE FINDINGS & FURTHER RECOMMENDATIONS

The ultrasonographic study reveals mild signs of chronic biceps tenosynovitis in the right shoulder. Clinical significance of such mild changes is highly variable, and it is considered rather unlikely that the relatively mild changes are able to fully explain both the clinical signs as well as the significant atrophy of the muscles around the scapula. The possibility of other concurrent diseases in the right thoracic limb or cervical spine including peripheral neuropathy should be considered.

REFERRING VET

Dr. Brian Barnes

INVOICE

59140

DATE

7-3-23



PATIENT

Phoebe Farnell

SPECIES

Canine

BREED

Airdale

SEX

FS

AGE

3 Years, 7 Months

INTERPRETED BY

Nele Eley, DVM
Dr. med. Vet. DipECVDI

HOSPITAL NAME

Westview Veterinary
Hospital

REFERRING VET

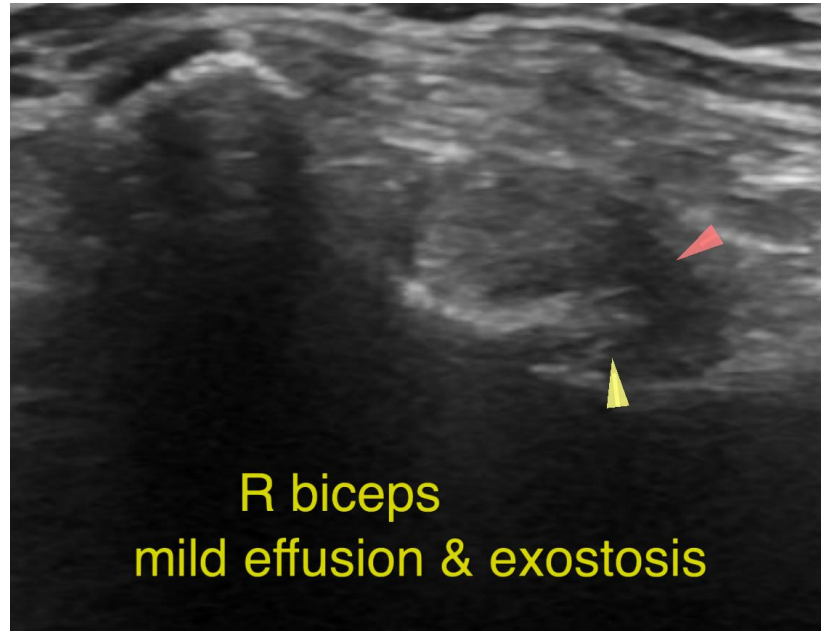
Dr. Brian Barnes

INVOICE

59140

DATE

7-3-23



The information and recommendations provided are based on the images presented by the referring veterinarian/sonographer. No evaluation can be communicated regarding pathology that was not visible in the image/video clips provided.

Thank you for this referral. If the clinical or image interpretation does not parallel your findings or if I can be of any further assistance please contact me.

Nele Eley, DVM, Dr. med. vet., DipECVDI
European Specialist in Veterinary Diagnostic Imaging, Cert. Radiology,
Senior lecturer University of Giessen, Germany, Veterinary Faculty, Department of Radiology
info@sonopath.com