



**PATIENT**

Scarlett Coskara

**PRESENTING CLINICAL SIGNS**

patient was presented today for limping on and off in the last couple of weeks eating and drinking normal no vomiting, diarrhea, coughing or sneezing  
Abnormal PE/Chem/CBC/UA Results: there is cranial drawer sign on right stifle

**SPECIES**

Canine

**RADIOGRAPHIC STUDY OF THE RIGHT STIFLE**

Mediolateral views of the right stifle and ventrodorsal hip extended view of the pelvis totaling 3 images available for review.

**BREED**

Cocker  
Spaniel/Poodle

**RADIOGRAPHIC FINDINGS**

There appears to be mild articular swelling of the right stifle joint. No obvious cranial thrust of the tibia is seen; however, the positioning is not optimized for the assessment of tibial shift. The subchondral bone surfaces are even and smooth. No significant osteophytes are present. The patella tendon is thin and well delineated.

**SEX**

FS

Mild atrophy of the right hind limb musculature is noted.

Review of the pelvis was not requested, however, both coxofemoral joints show signs of dysplasia and osteoarthritis.

**AGE**

2 Years

**RADIOGRAPHIC DIAGNOSIS**

- Mild articular swelling of the right stifle joint.
- Disuse atrophy of the right hind limb musculature.
- Note presence of bilateral hip dysplasia and coxofemoral joint osteoarthritis.

**INTERPRETED BY**

Nele Eley, DVM  
Dr. med. Vet. DipECVDI

**INTERPRETATION OF THE FINDINGS & FURTHER RECOMMENDATIONS**

**HOSPITAL NAME**

CJAH

No significant osteoarthritic changes of the right stifle are present and cranial thrust of the tibia cannot be confirmed radiographically, yet there appears to be mild articular swelling of the right stifle joint which may represent articular effusion as well as swelling of the synovial membrane or a combination of these.

**REFERRING VET**

Gabriel

The atrophy of the musculature indicates longer standing disuse of the right hind limb which may be associated with the stifle or coxofemoral joint pathology. Correlation with the clinical palpation is required.

**INVOICE**

52674

**DATE**

7-3-22



**PATIENT**

Scarlett Coskara

**SPECIES**

Canine

**BREED**

Cocker  
Spaniel/Poodle

**SEX**

FS

**AGE**

2 Years

**INTERPRETED BY**

Nele Eley, DVM  
Dr. med. Vet. DipECVDI

**HOSPITAL NAME**

CJAH

**REFERRING VET**

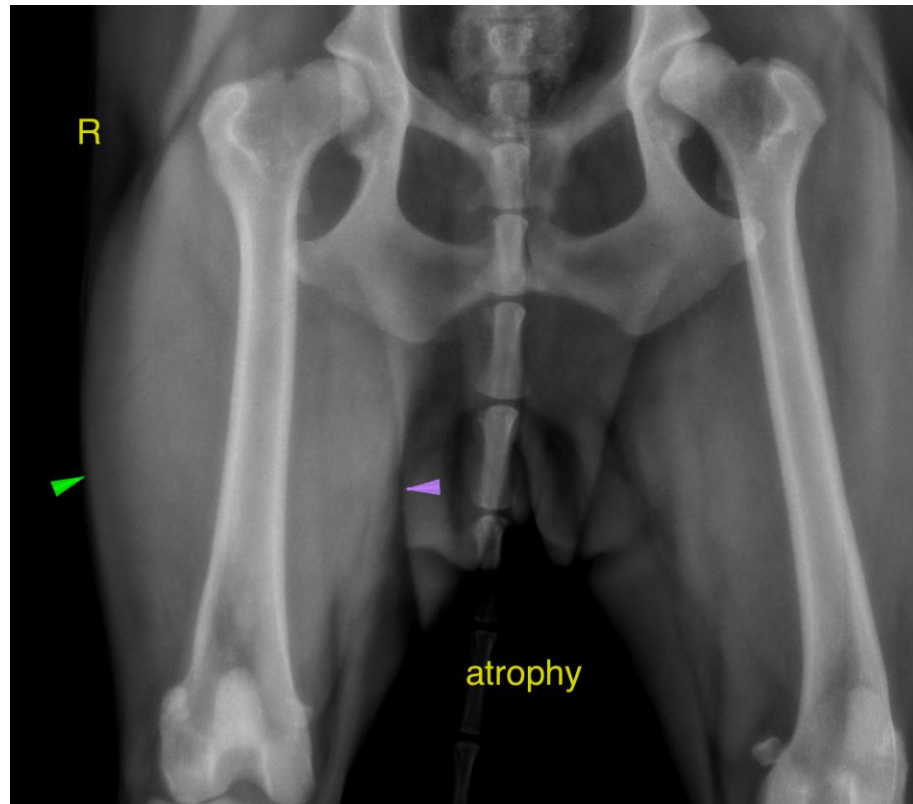
Gabriel

**INVOICE**

52674

**DATE**

7-3-22



The information and recommendations provided are based on the images presented by the referring veterinarian/sonographer. No evaluation can be communicated regarding pathology that was not visible in the image/video clips provided.

Thank you for this referral. If the clinical or image interpretation does not parallel your findings or if I can be of any further assistance please contact me.

**Nele Eley**, DVM, Dr. med. vet., DipECVDI  
European Specialist in Veterinary Diagnostic Imaging, Cert. Radiology,  
Senior lecturer University of Giessen, Germany, Veterinary Faculty, Department of Radiology  
Nele.Eley@sonopath.com