



PATIENT

Kylo Whitehall

PRESENTING CLINICAL SIGNS

Kylo is owned by one of our veterinary assistant's. Has IRIS stage 2 renal disease, no symptoms, no known toxin exposure, eating renal diet
 Abnormal PE/Chem/CBC/UA Results: BP is nl at 154 mm Hg Creat 2.1 mg/dL SDMA 16 ug/dL USG 1.013

SPECIES

Feline

RADIOGRAPHIC STUDY OF THE THORAX & ABDOMEN

Right/left lateral and ventrodorsal whole body views totaling 4 images available for review.

BREED

DLH

RADIOGRAPHIC FINDINGS

Thorax

The surrounding bony structures are within normal limits.

SEX

The extrathoracic soft tissues present homogeneous without abnormalities.

MN

The heart is of normal size and shape and there is no evidence of cardiac chamber or vascular enlargement. The pulmonary vasculature is within normal limits. The vertebral heart score is 7.5.

AGE

5 Years

The cranial mediastinum presents the expected soft tissue opacity. The mediastinal width is less than twice the width of the vertebral column at the same level.

INTERPRETED BY

Nele Eley, DVM
 Dr. med. Vet. DipECVDI

The trachea is normal in diameter and presents the anticipated course. The luminal outline of the trachea is smooth.

There is no evidence of air trapping; however, a moderate generalized bronchial lung pattern is seen and evenly distributed throughout the lung.

HOSPITAL NAME

Northshore
 Veterinary Hospital

The diaphragm is well delineated with even surface and the expected mild cranial bulging of the diaphragmatic cupola.

Abdomen

The surrounding bony structures are within normal limits.

REFERRING VET

Brita Kiffney

No abnormalities of the extraabdominal soft tissues are noted. The abdominal wall is smooth and thin.

The serosal detail is maintained throughout the peritoneal and retroperitoneal space.

INVOICE

53247

The liver is appropriate in position, size and presents uniform opacity.

The splenic head is in the anticipated position and within normal limits for size and opacity. The splenic tail is not seen.

DATE

7-29-22

Both kidneys are seen and present with normal size, shape, delineation and opacity. The urinary bladder is in its anticipated position. No radiopaque calculi are noted throughout the upper and lower urinary tract.



PATIENT

Kylo Whitehall

The stomach is in its anticipated position and presents normal content.

The small intestinal loops are of even diameter and non-dilated, a small amount of gas is seen within the small intestinal loops and considered within normal limits.

SPECIES

Feline

The colon is seen in the expected position and presents with appropriate content.

RADIOGRAPHIC DIAGNOSIS

BREED

DLH

- Moderate generalized bronchial lung pattern without concurrent air trapping.
- Normal radiographic presentation of the cardiac silhouette.
- Normal radiographic presentation of the abdomen.

INTERPRETATION OF THE FINDINGS & FURTHER RECOMMENDATIONS

SEX

MN

The bronchial lung pattern may be due to prior or current lower airway disease. Consider allergic lower airway syndrome a potential versus infectious bronchitis such as viral, bacterial, and less likely parasitic, or protozoal. Further definition would only be indicated in case of pertinent clinical signs.

AGE

5 Years

INTERPRETED BY

Nele Eley, DVM
Dr. med. Vet. DipECVDI

HOSPITAL NAME

Northshore
Veterinary Hospital

REFERRING VET

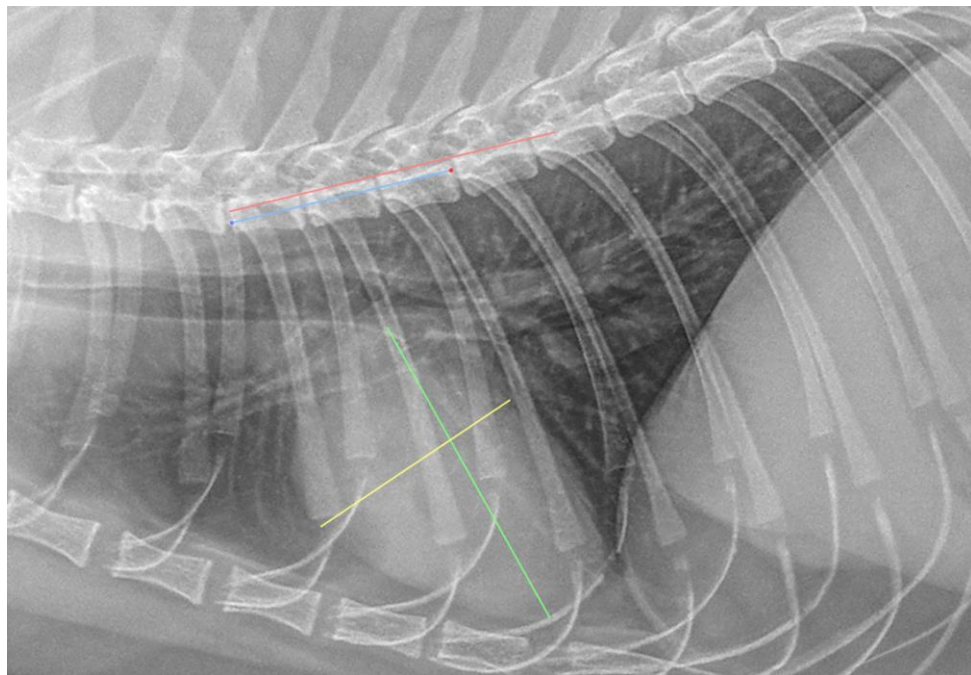
Brita Kiffney

INVOICE

53247

DATE

7-29-22





PATIENT

Kylo Whitehall

The information and recommendations provided are based on the images presented by the referring veterinarian/sonographer. No evaluation can be communicated regarding pathology that was not visible in the image/video clips provided.

Thank you for this referral. If the clinical or image interpretation does not parallel your findings or if I can be of any further assistance please contact me.

SPECIES

Feline

Nele Eley, DVM, Dr. med. vet., DipECVDI
European Specialist in Veterinary Diagnostic Imaging, Cert. Radiology,
Senior lecturer University of Giessen, Germany, Veterinary Faculty, Department of Radiology
Nele.Eley@sonopath.com

BREED

DLH

SEX

MN

AGE

5 Years

INTERPRETED BY

Nele Eley, DVM
Dr. med. Vet. DipECVDI

HOSPITAL NAME

Northshore
Veterinary Hospital

REFERRING VET

Brita Kiffney

INVOICE

53247

DATE

7-29-22