



PATIENT PRESENTING CLINICAL SIGNS

Riley Stump Riley presented for CT of thorax and abdomen, biopsies of subcutaneous masses over thorax and abdomen.

SPECIES COMPUTED TOMOGRAPHIC STUDY OF THE THORAX & ABDOMEN

Canine Post contrast studies available for review.

COMPUTED TOMOGRAPHIC FINDINGS

BREED

Abdomen

Staff Terr.

A large ovoid 15 x 11 cm sized uniformly fat attenuating mass with sparse vascularity is seen in the right lateral and caudal abdominal wall. The mass appears to splay the layers of the abdominal wall muscles. Severe thinning of the muscle layer to the peritoneal and retroperitoneal cavity is seen. No evidence of axial muscle or other peripheral tissue infiltration is seen.

SEX

FS

There is a 3.5 cm sized cavitating expansile mass of the spleen with strong heterogeneous contrast enhancement. Multiple hyperenhancing nodules are seen within the remainder of the spleen.

AGE

11 Years

The liver, pancreas, kidneys, adrenal glands, and abdominal lymph nodes present within age related normal limits.

INTERPRETED BY

Nele Eley, DVM
Dr. med. Vet. DipECVDI

There are multiple thoracolumbar spondyloses and severe degenerative lumbosacral stenosis with disc protrusion and spondylolysis deformans is noted.

The patient is obese.

HOSPITAL NAME

Critical Vet
Care/Suncoast
Veterinary

Thorax

The bronchopulmonary structures present within normal limits. No evidence of pulmonary nodules or masses is seen.

There is no evidence of mediastinal lymphadenomegaly.

REFERRING VET

Dr. Young

COMPUTED TOMOGRAPHIC DIAGNOSIS

- Large intermuscular lipoma within the right caudolateral abdominal wall.
- Expansile cavitating splenic mass and splenic nodules.
- Severe degenerative lumbosacral stenosis and multiple spondyloses.

INVOICE

53162

INTERPRETATION OF THE FINDINGS & FURTHER RECOMMENDATIONS

The CT study reveals a large abdominal wall lipoma in the right caudolateral abdominal wall. The mass appears to be extra-peritoneal, however, severe thinning of the muscle tissue between the lipoma and the abdominal wall muscles is noted. There is no structural evidence of liposarcoma or infiltrative lipoma.

DATE

7-28-22

Note the presence of a cavitating splenic mass. Differential diagnosis includes hemangiosarcoma,



PATIENT

Riley Stump

hemangioma, hematoma, and other. Multiple splenic nodules may represent benign nodular hyperplasia, extramedullary hematopoiesis, or metastatic disease. Splenectomy could be considered.

SPECIES

Canine

BREED

Staff Terr.

SEX

FS

AGE

11 Years

INTERPRETED BY

Nele Eley, DVM
Dr. med. Vet. DipECVDI

HOSPITAL NAME

Critical Vet
Care/Suncoast
Veterinary

REFERRING VET

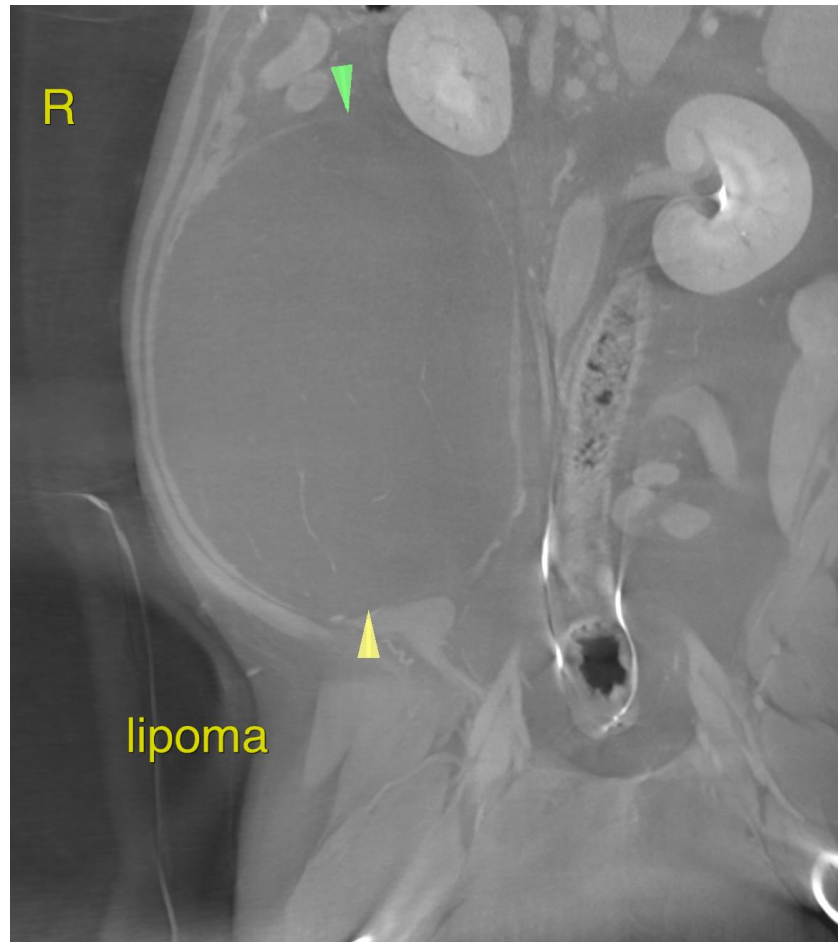
Dr. Young

INVOICE

53162

DATE

7-28-22





PATIENT

Riley Stump

SPECIES

Canine

BREED

Staff Terr.

SEX

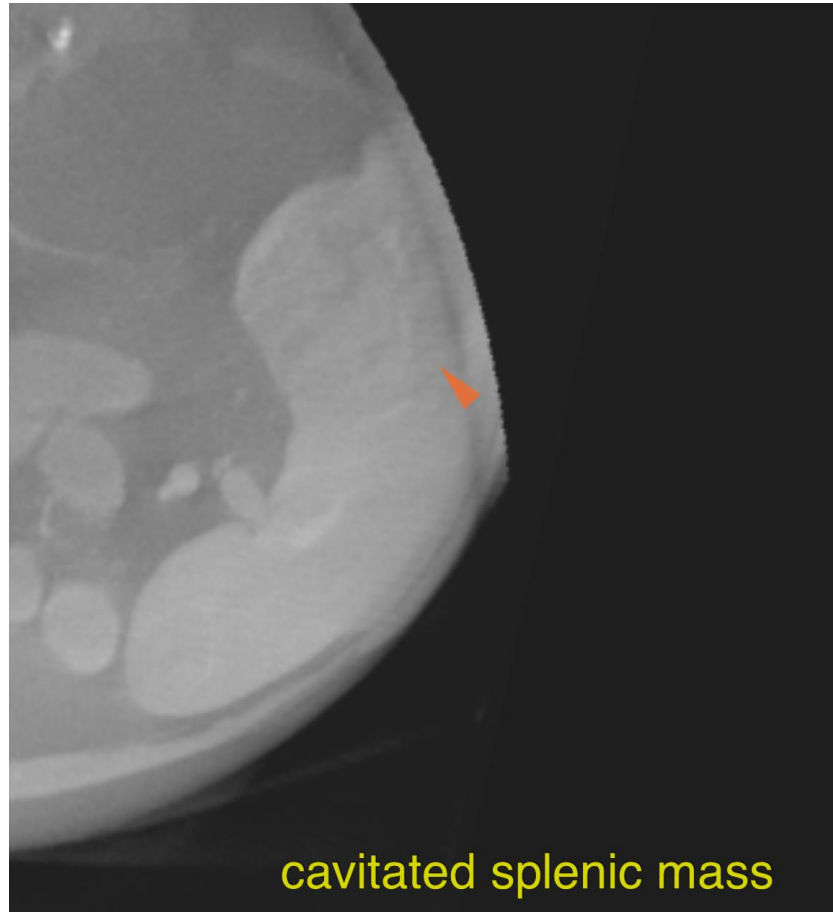
FS

AGE

11 Years

INTERPRETED BY

Nele Eley, DVM
Dr. med. Vet. DipECVDI



cavitated splenic mass

HOSPITAL NAME

Critical Vet
Care/Suncoast
Veterinary

The information and recommendations provided are based on the images presented by the referring veterinarian/sonographer. No evaluation can be communicated regarding pathology that was not visible in the image/video clips provided.

REFERRING VET

Dr. Young

Thank you for this referral. If the clinical or image interpretation does not parallel your findings or if I can be of any further assistance please contact me.

Nele Eley, DVM, Dr. med. vet., DipECVDI
European Specialist in Veterinary Diagnostic Imaging, Cert. Radiology,
Senior lecturer University of Giessen, Germany, Veterinary Faculty, Department of Radiology
Nele.Eley@sonopath.com

INVOICE

53162

DATE

7-28-22