



**PATIENT**

Hemi Menozzi

**PRESENTING CLINICAL SIGNS**

Fell off the bed and started holding right rear leg up. Has taken NSAIDs for a week since injury and he isn't any better. Lameness is intermittent, but frequent, throughout the day.

Abnormal PE/Chem/CBC/UA Results: Healthy dog other than mild lameness right rear. My colleague feels there is a slight meniscal click. No anterior drawer sign was evident. Radiographs were non remarkable.

**SPECIES**

Canine

**ULTRASONOGRAPHIC FINDINGS**

**BREED**

Lab Mix

**Right Stifle**

Mild effusion is noted in the infrapatellar recess of the right stifle. The suprapatellar recess was not scanned. There is a mild amount of osteophytes in the visible periarticular margins.

**SEX**

MN

The cranial cruciate ligament is continuous, yet it appears to be mildly irregular in outline and mildly thickened.

The medial meniscus was incompletely seen. Visible parts of the medial meniscus were in situ and no obvious injury could be identified.

**AGE**

7 Years

**ULTRASONOGRAPHIC DIAGNOSIS**

- Mild right stifle osteoarthritis with cranial cruciate ligament edema versus early partial rupture.

**INTERPRETED BY**

Nele Eley, DVM  
Dr. med. Vet. DipECVDI

**INTERPRETATION OF THE FINDINGS & FURTHER RECOMMENDATIONS**

The ultrasonographic findings suggest early partial rupture of the cranial cruciate ligament versus cruciate ligament edema. There is no direct evidence of meniscopathy, and I am not convinced of meniscopathy at all in this patient. Mild concurrent osteoarthritis is noted.

**HOSPITAL NAME**

Valley Veterinary  
Service Inc

Conservative management could be considered at this time with narrow clinical monitoring and repeat ultrasound should the clinical signs persist or deteriorate.

**REFERRING VET**

Michelle Bartus

**INVOICE**

53160

**DATE**

7-28-22



**PATIENT**

Hemi Menozzi

**SPECIES**

Canine

**BREED**

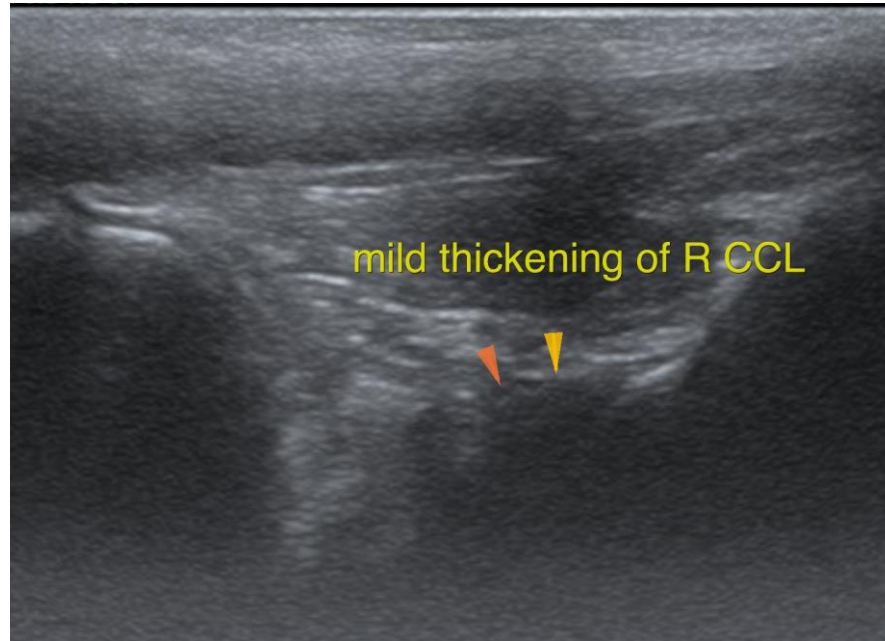
Lab Mix

**SEX**

MN

**AGE**

7 Years



**INTERPRETED BY**

Nele Eley, DVM  
Dr. med. Vet. DipECVDI

**HOSPITAL NAME**

Valley Veterinary  
Service Inc

**REFERRING VET**

Michelle Bartus

**INVOICE**

53160

**DATE**

7-28-22

The information and recommendations provided are based on the images presented by the referring veterinarian/sonographer. No evaluation can be communicated regarding pathology that was not visible in the image/video clips provided.

Thank you for this referral. If the clinical or image interpretation does not parallel your findings or if I can be of any further assistance please contact me.

**Nele Eley**, DVM, Dr. med. vet., DipECVDI  
European Specialist in Veterinary Diagnostic Imaging, Cert. Radiology,  
Senior lecturer University of Giessen, Germany, Veterinary Faculty, Department of Radiology  
Nele.Eley@sonopath.com