



PATIENT

Chase Savolainen

PRESENTING CLINICAL SIGNS

presented for cryptorchid testicle, Abdominal U/S performed July 27th and unable to find retained testicle. CT performed of abdomen prior to ex-lap

SPECIES

Canine

COMPUTED TOMOGRAPHIC STUDY OF THE ABDOMEN

Plain and post contrast studies available for review.

BREED

German Shepherd

COMPUTED TOMOGRAPHIC FINDINGS

The right testicle is in the expected position within the scrotum. No left testicle is seen within the scrotum or in the area of the inguinal ring.

An elongated soft tissue attenuating structure of 14 x 7mm is seen dorsal to the cranial pole of the urinary bladder. The deferent duct can be seen coursing laterally from this structure.

SEX

M

COMPUTED TOMOGRAPHIC DIAGNOSIS

- Hypoplastic left abdominal testicle.

AGE

1 Year

INTERPRETATION OF THE FINDINGS & FURTHER RECOMMENDATIONS

The nondistended testicle can be localized in the abdominal cavity in this CT study and is positioned dorsal to the urinary bladder. Note the small size of the testicle which suggests hypoplasia and may pose a challenge to the surgical removal.

INTERPRETED BY

Nele Eley, DVM
Dr. med. Vet. DipECVDI

HOSPITAL NAME

Animal Health
Partners

REFERRING VET

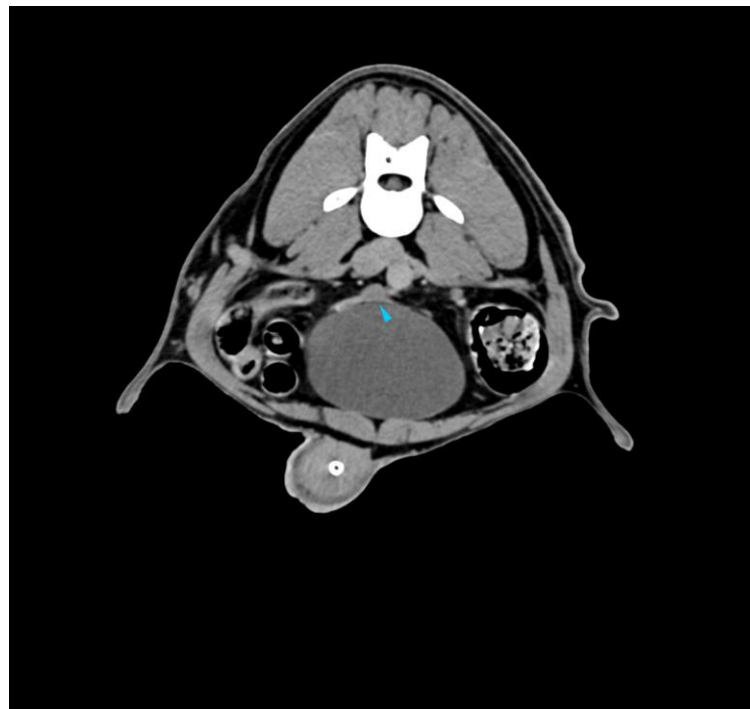
Dr. Jeffery Biskup

INVOICE

53152

DATE

7-27-22





PATIENT

Chase Savolainen

SPECIES

Canine

BREED

German Shepherd

SEX

M

AGE

1 Year

INTERPRETED BY

Nele Eley, DVM
Dr. med. Vet. DipECVDI

HOSPITAL NAME

Animal Health
Partners

REFERRING VET

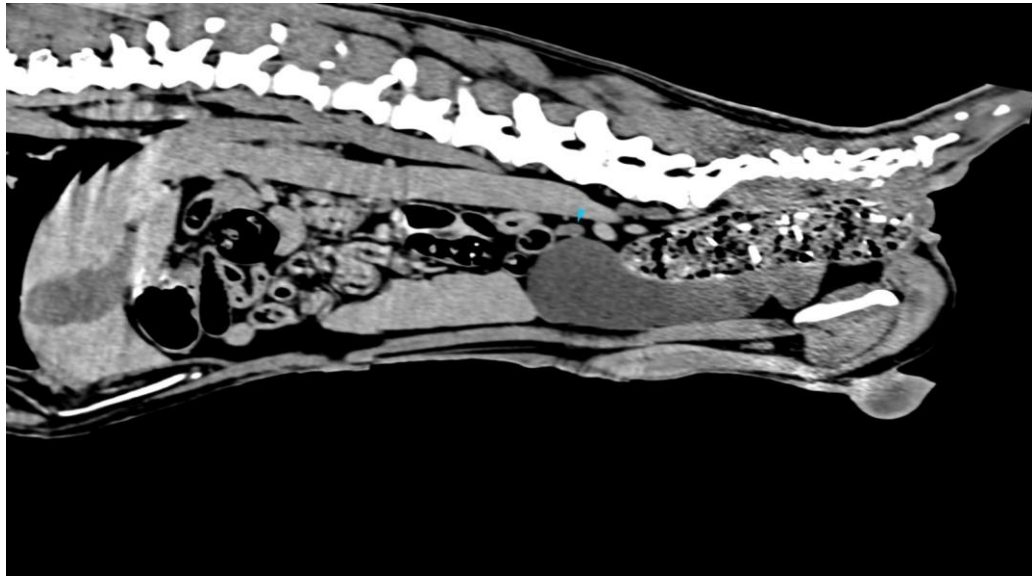
Dr. Jeffery Biskup

INVOICE

53152

DATE

7-27-22



The information and recommendations provided are based on the images presented by the referring veterinarian/sonographer. No evaluation can be communicated regarding pathology that was not visible in the image/video clips provided.

Thank you for this referral. If the clinical or image interpretation does not parallel your findings or if I can be of any further assistance please contact me.

Nele Eley, DVM, Dr. med. vet., DipECVDI
European Specialist in Veterinary Diagnostic Imaging, Cert. Radiology,
Senior lecturer University of Giessen, Germany, Veterinary Faculty, Department of Radiology
Nele.Eley@sonopath.com