



PATIENT

Benny Corcoran

PRESENTING CLINICAL SIGNS

spontaneous fracture during off leash exercise in Jan22 - biopsy and repair - screw loosening and removal (uneventful), no lameness - lame progressive July22
Abnormal PE/Chem/CBC/UA Results: cbc/chem wl

SPECIES

Canine

RADIOGRAPHIC STUDY OF THE LEFT HUMERUS

Mediolateral and craniocaudal views of the left humerus and right lateral and ventrodorsal views of the thorax totaling 4 images available for review.

BREED

Greyhound

RADIOGRAPHIC FINDINGS

Patient has a history of left humeral fracture in January 2020 with open reduction and internal fixation.

SEX

The surgical implant is in situ.

MN

An area of severely reduced bone opacity is seen in the proximal left humerus in the region of the 1st, 2nd, and 3rd proximal screws. Severely reduced cortical thickness is noted in this area as well as reduced medullary bone opacity. Cortical thickening is seen in the fractured area. Heterogeneous and sclerotic callous is seen bridging the fractured area on the orthogonal views. Hypertrophic callous formation is seen in the caudal aspect of the fracture area in the mid diaphysis. Mildly reduced bone opacity is seen circumferential to the distal screws.

AGE

8

INTERPRETED BY

Nele Eley, DVM
Dr. med. Vet. DipECVDI

There is a defect in the area of the biopsy in the proximal cortex of the humerus which has not been filled with bone yet.

RADIOGRAPHIC DIAGNOSIS

- Suspect delayed union in late reparation phase of the left humerus after traumatic osseous injury more than 6 months ago.
- Severely reduced bone opacity accentuating the left proximal humerus.

HOSPITAL NAME

Advanced Veterinary
Imaging

INTERPRETATION OF THE FINDINGS & FURTHER RECOMMENDATIONS

The radiographic findings suggest a delayed union of the left humerus fracture as the osseous remodeling does not appear to have started yet, at least not significantly. The reduction in bone opacity is accentuated in the proximal humerus and may represent atrophy secondary to disuse as well as implant reaction or necrosis. However, early surgical site sarcoma or osteosarcoma cannot be ruled out entirely and further clinical and radiographic monitoring are advised.

REFERRING VET

Eamon

INVOICE

53113

DATE

7-27-22



PATIENT

Benny Corcoran

SPECIES

Canine

BREED

Greyhound

SEX

MN

AGE

8

INTERPRETED BY

Nele Eley, DVM
Dr. med. Vet. DipECVDI

HOSPITAL NAME

Advanced Veterinary
Imaging

REFERRING VET

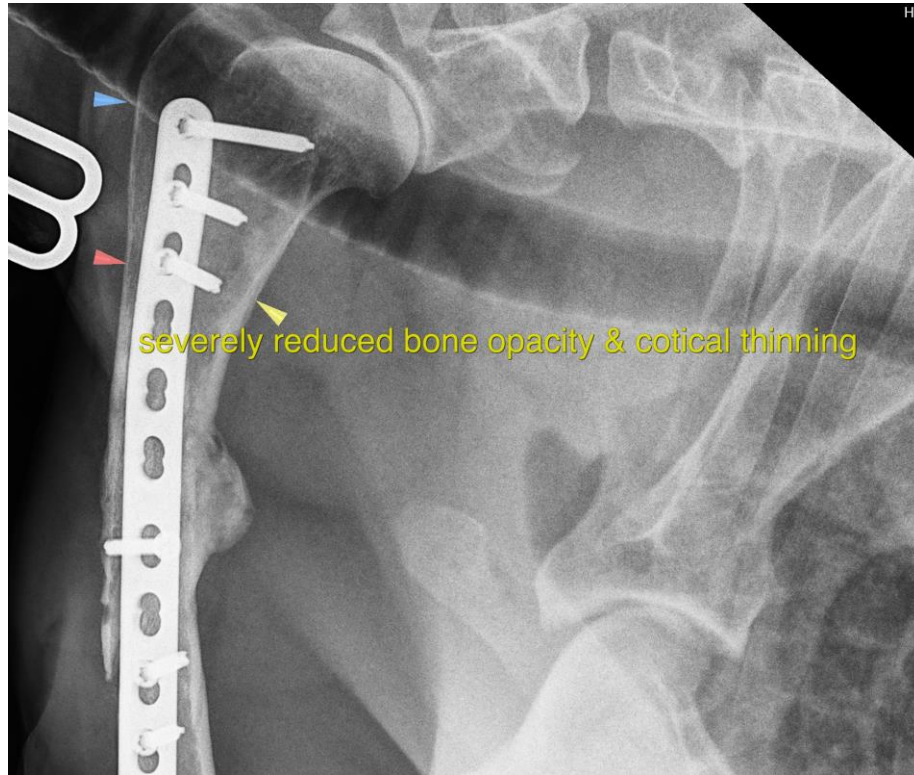
Eamon

INVOICE

53113

DATE

7-27-22



The information and recommendations provided are based on the images presented by the referring veterinarian/sonographer. No evaluation can be communicated regarding pathology that was not visible in the image/video clips provided.

Thank you for this referral. If the clinical or image interpretation does not parallel your findings or if I can be of any further assistance please contact me.

Nele Eley, DVM, Dr. med. vet., DipECVDI
European Specialist in Veterinary Diagnostic Imaging, Cert. Radiology,
Senior lecturer University of Giessen, Germany, Veterinary Faculty, Department of Radiology
Nele.Eley@sonopath.com