



PATIENT PRESENTING CLINICAL SIGNS

Sprite Kelly
 Presents for right sided epistaxis x few days. H/O coughing, wheezing that started a few months ago at time of household having COVID. Lungs and heart auscult normal. Firm swelling over right nasal sinuses. Right mandibular and right prescapular LN enlargement.
SPECIES Abnormal PE/Chem/CBC/UA Results: High monocytic neutrophilic leukocytosis

Ca RADIOGRAPHIC STUDY OF THE THORAX

Right/left lateral and ventrodorsal views of the thorax totaling 3 images available for review.

BREED RADIOGRAPHIC FINDINGS

Mixed
 Mild shoulder osteoarthritis is noted.

SEX
 MN
 Two soft tissue opaque pulmonary nodules of 2.5 and 2.7 cm diameter respectively are seen within the left cranial and right caudal lung lobes. The remainder of the pulmonary parenchyma presents a mild bronchial pattern. Multiple age related incidental pulmonary osteomas are seen.

Course and width of the trachea are considered within normal limits.

AGE
 13
 There is no evidence of concurrent mediastinal lymphadenomegaly or pleural effusion.

RADIOGRAPHIC DIAGNOSIS

- Interstitial pulmonary nodules.

INTERPRETATION OF THE FINDINGS & FURTHER RECOMMENDATIONS

The radiographic study reveals a structured nodular lung pattern with two large interstitial nodules within the left cranial and right caudal lung lobes. The findings are highly suggestive for neoplastic pulmonary disease with metastatic disease of another primary tumor being one primary differential diagnosis, as well as secondary neoplasia of the lung such as round cell neoplasia or sarcoma. The potential for fungal or other granuloma is considered highly unlikely in light of both the radiographic findings and the clinical history of the patient, and this should be regarded as metastatic disease until proven otherwise.

INTERPRETED BY

Nele Eley, DVM
 Dr. med. Vet. DipECVDI

HOSPITAL NAME

Torch Lake
 Veterinary Clinic

REFERRING VET

Jen Rudnick

INVOICE

53098

DATE

7-26-22



PATIENT

Sprite Kelly

SPECIES

Ca

BREED

Mixed

SEX

MN

AGE

13

INTERPRETED BY

Nele Eley, DVM
Dr. med. Vet. DipECVDI

HOSPITAL NAME

Torch Lake
Veterinary Clinic

REFERRING VET

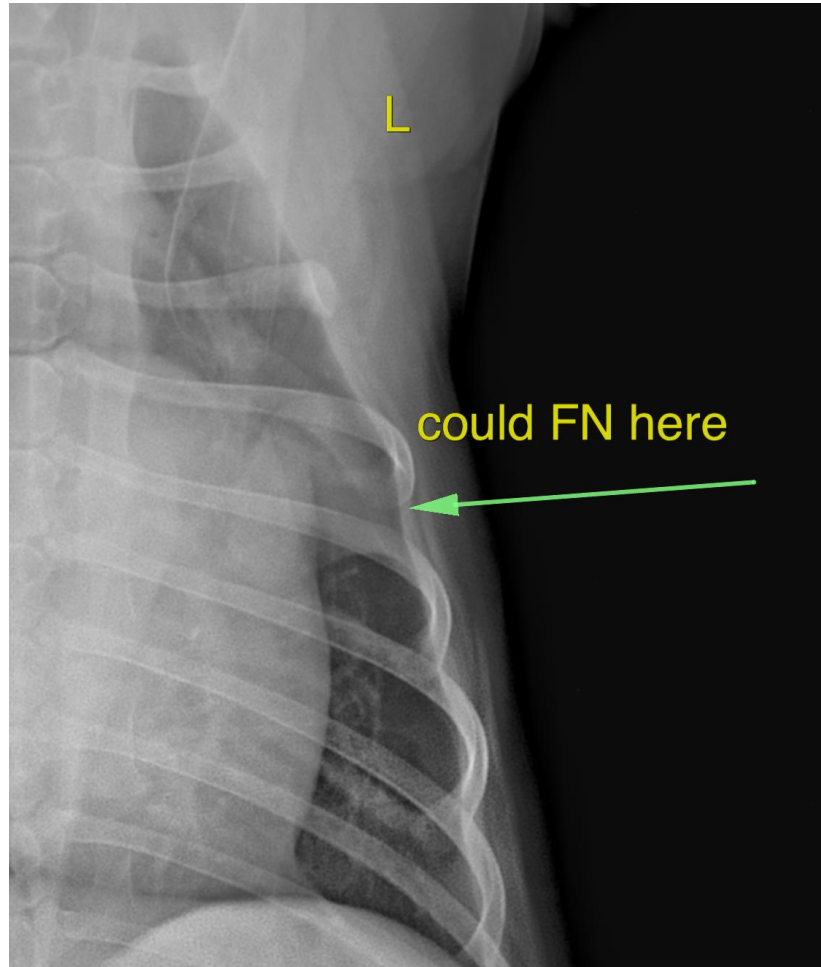
Jen Rudnick

INVOICE

53098

DATE

7-26-22



The information and recommendations provided are based on the images presented by the referring veterinarian/sonographer. No evaluation can be communicated regarding pathology that was not visible in the image/video clips provided.

Thank you for this referral. If the clinical or image interpretation does not parallel your findings or if I can be of any further assistance please contact me.

Nele Eley, DVM, Dr. med. vet., DipECVDI
European Specialist in Veterinary Diagnostic Imaging, Cert. Radiology,
Senior lecturer University of Giessen, Germany, Veterinary Faculty, Department of Radiology
Nele.Eley@sonopath.com