

**PATIENT**

Fred Reid

**PRESENTING CLINICAL SIGNS**

Hacking cough started 3 weeks ago, getting worse in the last few days. No V/D Eating well. Red conjunctiva in both eye., another dog in the house has pink eye. HR = 70bpm  
Abnormal PE/Chem/CBC/UA Results: Eosinophils mild elevated otherwise normal T4 normal

**SPECIES**

Canine

**RADIOGRAPHIC STUDY OF THE THORAX**

Right/left lateral and ventrodorsal views of the thorax totaling 3 images available for review.

**BREED**

Doodle X

**RADIOGRAPHIC FINDINGS**

The vertebral heart score is 9.6.

Course and width of the trachea are considered within normal limits.

**SEX**

Male Neuter

There is no evidence of mediastinal lymphadenomegaly or other abnormal mediastinal widening.

A moderate bronchointerstitial lung pattern accentuating the caudal and dorsal lung with marked peribronchial cuffing is seen.

**AGE**

5 Years

The thoracic boundaries present within normal limits.

**RADIOGRAPHIC DIAGNOSIS**

- Moderate active bronchointerstitial lung pattern.

**INTERPRETED BY**

Nele Eley, DVM  
Dr. med. Vet. DipECVDI

**INTERPRETATION OF THE FINDINGS & FURTHER RECOMMENDATIONS**

The radiographic findings are highly suggestive for lower airway disease such as infectious bronchitis including viral, bacterial, and less likely parasitic versus eosinophilic / allergic bronchopneumopathy. Consider a clinical trial of treatment for infectious bronchitis versus further definition by means of airway endoscopy with airway sampling.

**HOSPITAL NAME**

St. Catherine's Animal  
Hospital

**REFERRING VET**

Dr. Bekhit

**INVOICE**

53064

**DATE**

7-25-22



**PATIENT**

Fred Reid

**SPECIES**

Canine

**BREED**

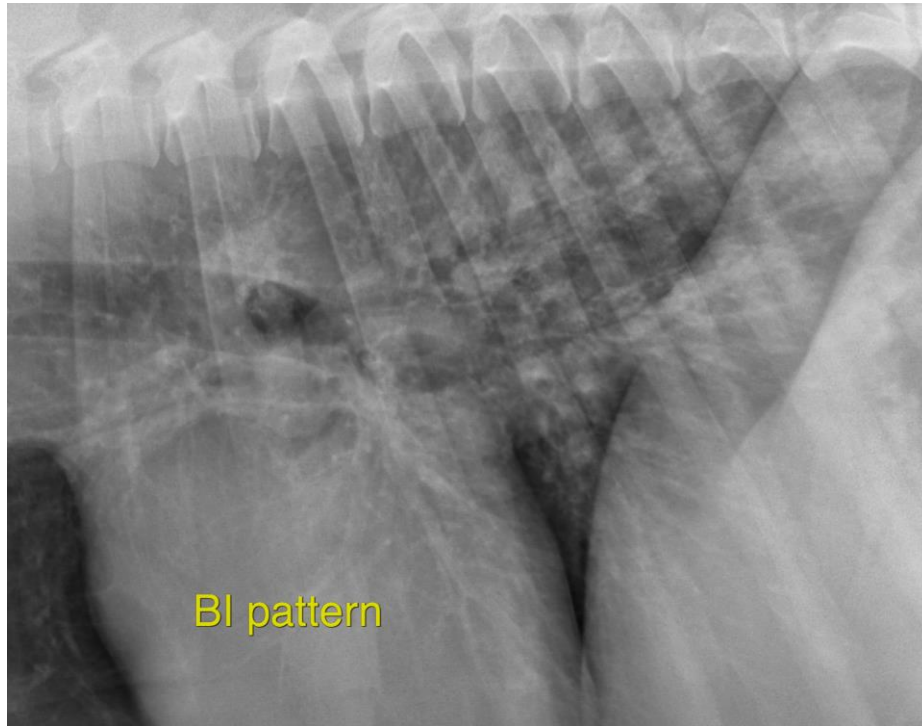
Doodle X

**SEX**

Male Neuter

**AGE**

5 Years



**INTERPRETED BY**

Nele Eley, DVM  
Dr. med. Vet. DipECVDI

The information and recommendations provided are based on the images presented by the referring veterinarian/sonographer. No evaluation can be communicated regarding pathology that was not visible in the image/video clips provided.

**HOSPITAL NAME**

St. Catherine's Animal  
Hospital

Thank you for this referral. If the clinical or image interpretation does not parallel your findings or if I can be of any further assistance please contact me.

**Nele Eley**, DVM, Dr. med. vet., DipECVDI  
European Specialist in Veterinary Diagnostic Imaging, Cert. Radiology,  
Senior lecturer University of Giessen, Germany, Veterinary Faculty, Department of Radiology  
Nele.Eley@sonopath.com

**REFERRING VET**

Dr. Bekhit

**INVOICE**

53064

**DATE**

7-25-22