



PATIENT PRESENTING CLINICAL SIGNS

Flo Forward TECA-Bo performed 3 yrs ago - staph infect post operatively Bilateral cataract replacement 2 yrs
1mnt hx head tilt (intermittent) bilateral - aggression (very abnormal)
Abnormal PE/Chem/CBC/UA Results: pending

SPECIES COMPUTED TOMOGRAPHIC STUDY OF THE HEAD

Canine Plain and post contrast studies in soft tissue and bone windows available for review.

BREED COMPUTED TOMOGRAPHIC FINDINGS

Boxer X Bilateral artificial lenses are seen.
Patient has a history of bilateral ear canal ablation.

SEX Moderate swelling of the mucosal lining of both tympanic bullae is seen. A moderate amount of fluid attenuating material with a meniscal sign is seen within the left tympanic bulla. Mild thickening of the osseous lining of the left tympanic bulla is noted.

FN

AGE The regional lymph nodes present within normal limits.

12

No structural brain injury can be seen. The neuroparenchymal anatomy, symmetry, attenuation, and enhancement presents within normal limits. The ventricular system presents within normal limits. There is no evidence of abnormal meningeal enhancement.

INTERPRETED BY COMPUTED TOMOGRAPHIC DIAGNOSIS

Nele Eley, DVM
Dr. med. Vet. DipECVDI

- History of bilateral total ear canal ablation.
- Moderate bilateral otitis media – left more than right.
- No evidence of structural brain injury and no evidence of intracranial extension of the otitis media.

HOSPITAL NAME INTERPRETATION OF THE FINDINGS & FURTHER RECOMMENDATIONS

Advanced Veterinary
Imaging

The CT study reveals no evidence of structural brain injury. Early infiltrative disease, inflammatory/infectious, metabolic/toxic, and cerebrovascular pathology cannot be ruled out. Consider complementary csf analysis. An MRI could be considered for further definition should the csf analysis remain inconclusive and should the clinical signs of the patient persist.

REFERRING VET

Eamon

The necessity of bulla osteotomy could be discussed in this patient.

INVOICE

53055

DATE

7-25-22



PATIENT

Flo Forward

SPECIES

Canine

BREED

Boxer X

SEX

FN

AGE

12

INTERPRETED BY

Nele Eley, DVM
Dr. med. Vet. DipECVDI

HOSPITAL NAME

Advanced Veterinary
Imaging

REFERRING VET

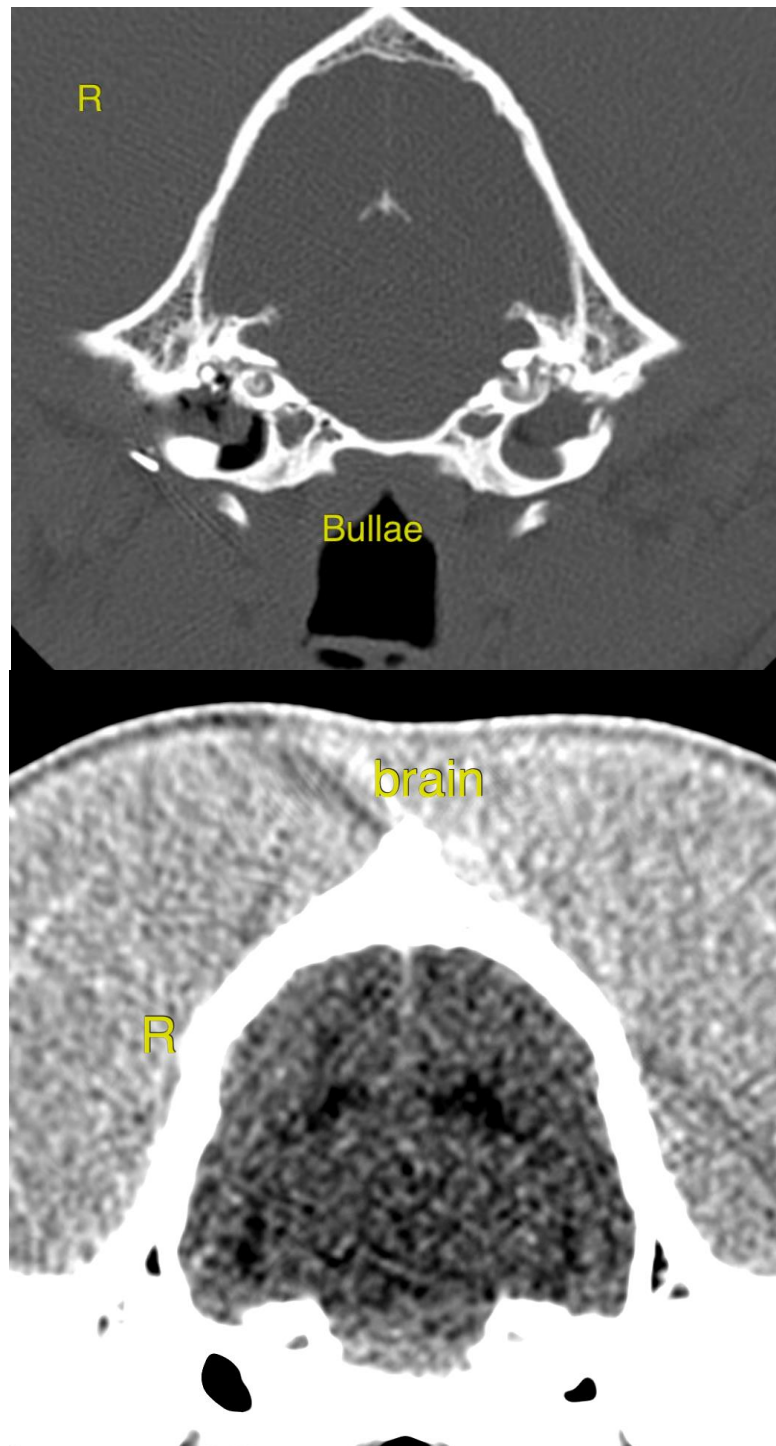
Eamon

INVOICE

53055

DATE

7-25-22





PATIENT

Flo Forward

The information and recommendations provided are based on the images presented by the referring veterinarian/sonographer. No evaluation can be communicated regarding pathology that was not visible in the image/video clips provided.

Thank you for this referral. If the clinical or image interpretation does not parallel your findings or if I can be of any further assistance please contact me.

SPECIES

Canine

Nele Eley, DVM, Dr. med. vet., DipECVDI
European Specialist in Veterinary Diagnostic Imaging, Cert. Radiology,
Senior lecturer University of Giessen, Germany, Veterinary Faculty, Department of Radiology
Nele.Eley@sonopath.com

BREED

Boxer X

SEX

FN

AGE

12

INTERPRETED BY

Nele Eley, DVM
Dr. med. Vet. DipECVDI

HOSPITAL NAME

Advanced Veterinary
Imaging

REFERRING VET

Eamon

INVOICE

53055

DATE

7-25-22