



PATIENT

Cookie Rivera

PRESENTING CLINICAL SIGNS

Patient presented with history of seizures episodes since June 8. Incoordination, rigid owner states patient episodes. Started on Keppra and Prednisolone. ON recheck owner noticed improving and start with tremors. On June 27 patient presented partial blindness and lost of smell. July 8 on PE patient is full blind, L side circling. Seizures episodes are sporadic. Abnormal PE/Chem/CBC/UA Results: CBC --- unremarkable CHEM --- unremarkable Snap 4Dx --- negativePatient

SPECIES

Canine

COMPUTED TOMOGRAPHIC STUDY OF THE HEAD

BREED

Shih Tzu

Plain and post contrast studies available for review.

COMPUTED TOMOGRAPHIC FINDINGS

SEX

SF

Regional abnormal heterogeneous contrast enhancement is noted in the caudal aspect of the left cerebral hemisphere level with the occipital and temporal lobes. The pattern of enhancement suggests potential for both neuroparenchymal / cortical as well as leptomeningeal involvement. A mild mass effect appears to be present.

AGE

6 Years

Mild swelling of the mucosal lining is noted within the mesotympanum of both tympanic bullae. The osseous lining of the tympanic bullae presents within normal limits. The osseous structures within the inner ear present within normal limits. The external auditory meatuses are patent.

The lymph nodes of the head present within normal limits.

INTERPRETED BY

Nele Eley, DVM
Dr. med. Vet. DipECVDI

COMPUTED TOMOGRAPHIC DIAGNOSIS

- Meningeal encephalopathy with regional and asymmetric distribution to the left occipital and temporal lobes.
- Mild bilateral otitis media.

HOSPITAL NAME

Veterinary Image Center

INTERPRETATION OF THE FINDINGS & FURTHER RECOMMENDATIONS

The CT study reveals left sided meningeal encephalopathy with asymmetric distribution, abnormal contrast enhancement, and mild mass effect. Differential diagnosis includes inflammatory/infectious brain disease as well as an interaxial neoplastic infiltrate and less likely cerebrovascular disease. Consider complementary csf analysis for further definition if not performed already. If this remains inconclusive, an MRI could be considered for further definition.

REFERRING VET

Dr. M. Davila, DVM

INVOICE

53058

DATE

7-25-22



PATIENT

Cookie Rivera

SPECIES

Canine

BREED

Shih Tzu

SEX

SF

AGE

6 Years

INTERPRETED BY

Nele Eley, DVM
Dr. med. Vet. DipECVDI

HOSPITAL NAME

Veterinary Image
Center

REFERRING VET

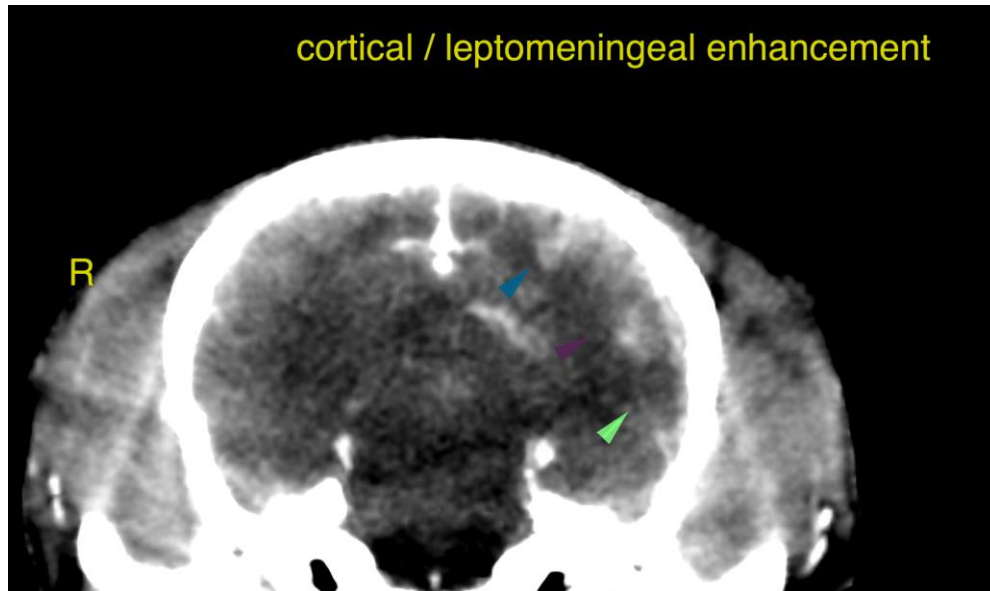
Dr. M. Davila, DVM

INVOICE

53058

DATE

7-25-22



The information and recommendations provided are based on the images presented by the referring veterinarian/sonographer. No evaluation can be communicated regarding pathology that was not visible in the image/video clips provided.

Thank you for this referral. If the clinical or image interpretation does not parallel your findings or if I can be of any further assistance please contact me.

Nele Eley, DVM, Dr. med. vet., DipECVDI
European Specialist in Veterinary Diagnostic Imaging, Cert. Radiology,
Senior lecturer University of Giessen, Germany, Veterinary Faculty, Department of Radiology
Nele.Eley@sonopath.com