

**PATIENT**

Kalliope Irahetajuarez

PRESENTING CLINICAL SIGNS

Patient was bit in the face by larger german shepherd

SPECIES

Canine

COMPUTED TOMOGRAPHIC STUDY OF THE HEAD

Plain study available for review.

BREED

German Shepherd

COMPUTED TOMOGRAPHIC FINDINGS

The calvarium and skull base are intact. The temporomandibular joints and mandibles are intact.

SEX

Female

There is a comminuted fracture of the caudal aspect of the right maxilla which blends into multiple small fracture fragments of the rostral part of the right zygomatic arch. Regional soft tissue swelling, and emphysema are noted. No direct injury of the right eye can be seen, however, there is regional soft tissue swelling and emphysema within the mid and rostral aspect of the right orbita as well. The maxillary fractures do involve the dental alveoli and anlagen of the triadans 108 and 109. The alveolus and anlage of the triadan 110 is caudal to the fractured area.

The nasal cavities and frontal sinuses appear to be intact.

AGE

13 Weeks

COMPUTED TOMOGRAPHIC DIAGNOSIS

- Soft tissue swelling with emphysema after recent bite injury as well as comminuted open right maxillary and right zygomatic arch fractures involving the alveoli and anlagen of the triadans 108 and 109.

INTERPRETED BYNele Eley, DVM
Dr. med. Vet. DipECVDI**INTERPRETATION OF THE FINDINGS & FURTHER RECOMMENDATIONS**

The CT study reveals extensive soft tissue injury in the right side of the face. Ophthalmologic workup is recommended in order to rule out direct involvement of the right eye. The calvarium and skull base are intact. The temporomandibular joints are intact. There is an open comminuted fracture of the right caudal maxilla and rostral part of the zygomatic arch. Infection and injury to the dental alveoli and anlagen of the triadans 108 and 109 should be considered a potential. Maxillary and mandibular symphyses and hard palate are intact.

HOSPITAL NAME

Wilvet Salem

REFERRING VET

Dr. Anna Wepprich

INVOICE

53034

DATE

7-24-22



PATIENT

Kalliope Irahetajuarez

SPECIES

Canine

BREED

German Shepherd

SEX

Female

AGE

13 Weeks

INTERPRETED BY

Nele Eley, DVM
Dr. med. Vet. DipECVDI

HOSPITAL NAME

Wilvet Salem

REFERRING VET

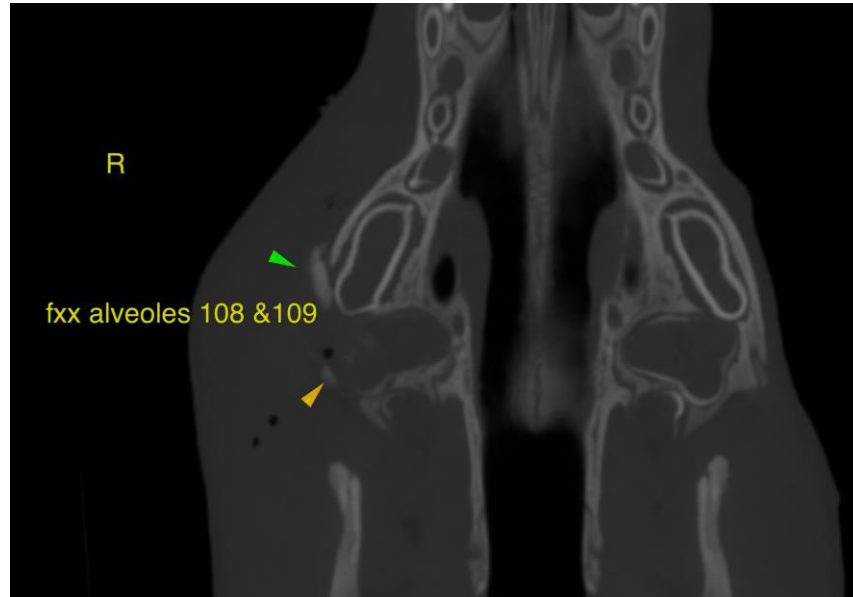
Dr. Anna Wepprich

INVOICE

53034

DATE

7-24-22



The information and recommendations provided are based on the images presented by the referring veterinarian/sonographer. No evaluation can be communicated regarding pathology that was not visible in the image/video clips provided.

Thank you for this referral. If the clinical or image interpretation does not parallel your findings or if I can be of any further assistance please contact me.

Nele Eley, DVM, Dr. med. vet., DipECVDI
European Specialist in Veterinary Diagnostic Imaging, Cert. Radiology,
Senior lecturer University of Giessen, Germany, Veterinary Faculty, Department of Radiology
Nele.Eley@sonopath.com