



PATIENT

Beauty Duncan

SPECIES

Canine

BREED

Pit Bull Mix

SEX

FS

AGE

8 Years

INTERPRETED BY

Nele Eley, DVM
Dr. med. Vet. DipECVDI

HOSPITAL NAME

Healing Spirit Animal
Wellness

REFERRING VET

Lea Schroeder

INVOICE

53050

DATE

7-24-22

PRESENTING CLINICAL SIGNS

Referred for CT due to history of neurologic signs including ataxia several weeks duration, diminished cognitive function, suspected decrease of smell and vision, recent onset seizures
Abnormal PE/Chem/CBC/UA Results: obtunded mentation on exam, tonic/ clonic seizure immediately prior to anesthesia. Mild ALT elevation reported on chemistry

COMPUTED TOMOGRAPHIC STUDY OF THE HEAD

Plain and post contrast studies available for review.

COMPUTED TOMOGRAPHIC FINDINGS

The CT study reveals deviation of the cerebral midline towards the right side level with the frontal and temporal lobes of the brain. No abnormal attenuation or enhancement can be identified in the left cerebral hemisphere.

Mild bilateral lateral ventriculomegaly is noted.

There is significant asymmetry of the neurocranium accentuating the region of the frontal bones.

COMPUTED TOMOGRAPHIC DIAGNOSIS

- Suspect presence of an intraaxial mass effect within the left cerebral hemisphere.
- Skull asymmetry.

INTERPRETATION OF THE FINDINGS & FURTHER RECOMMENDATIONS

The CT findings are highly suggestive for the presence of intraaxial brain pathology with mass effect within the left cerebral hemisphere. The CT findings are unspecific and differential diagnosis includes intraaxial neoplasia, cerebrovascular disease, and other brain pathology with edema, inflammatory/infectious disease, and other. Further verification and definition of the CT changes by means of an MRI could be considered in case of persisting or recurrent clinical signs or should the patient remain refractory to anticonvulsive medication.

The degree and anatomic distribution of the skull asymmetry does not suffice to explain the asymmetry of the neuroparenchyma.



PATIENT

Beauty Duncan

SPECIES

Canine

BREED

Pit Bull Mix

SEX

FS

AGE

8 Years

INTERPRETED BY

Nele Eley, DVM
Dr. med. Vet. DipECVDI

HOSPITAL NAME

Healing Spirit Animal
Wellness

REFERRING VET

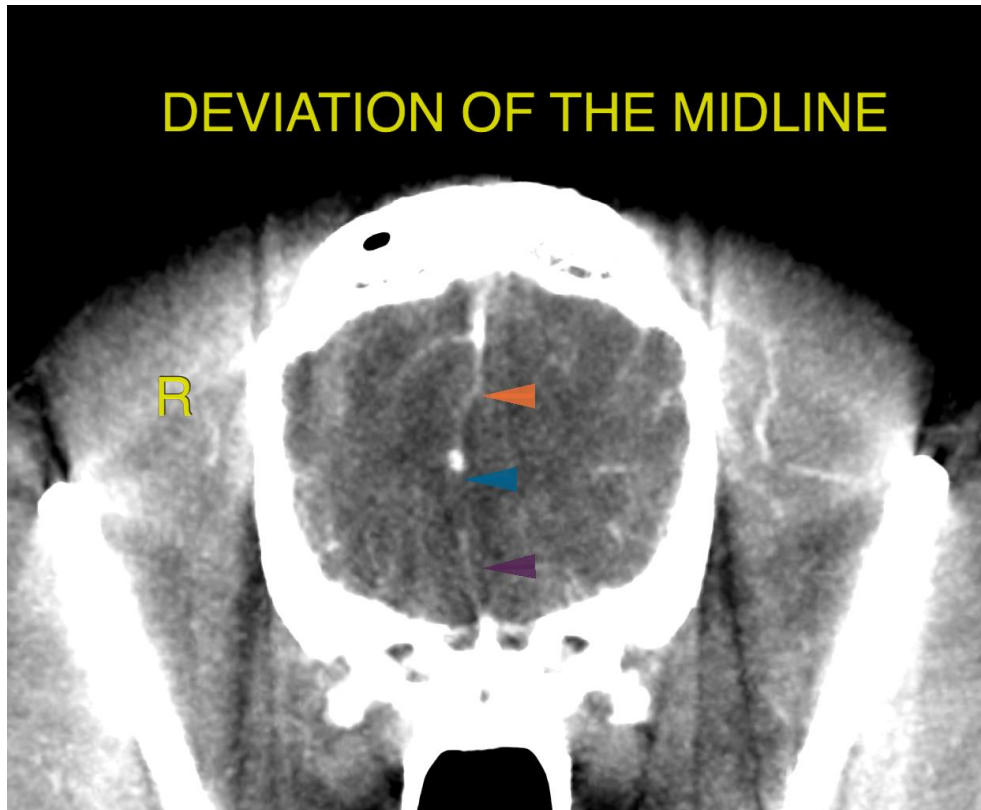
Lea Schroeder

INVOICE

53050

DATE

7-24-22



The information and recommendations provided are based on the images presented by the referring veterinarian/sonographer. No evaluation can be communicated regarding pathology that was not visible in the image/video clips provided.

Thank you for this referral. If the clinical or image interpretation does not parallel your findings or if I can be of any further assistance please contact me.

Nele Eley, DVM, Dr. med. vet., DipECVDI
European Specialist in Veterinary Diagnostic Imaging, Cert. Radiology,
Senior lecturer University of Giessen, Germany, Veterinary Faculty, Department of Radiology
Nele.Eley@sonopath.com