



PATIENT PRESENTING CLINICAL SIGNS

Penny Wada left anal sac mass and sublumbar lymphadenopathy
 Abnormal PE/Chem/CBC/UA Results: cbc and chem is normal

SPECIES COMPUTED TOMOGRAPHIC STUDY OF THE ABDOMEN

Canine Post contrast study available for review.
 Study is right/left flipped.

BREED COMPUTED TOMOGRAPHIC FINDINGS

Pitbull Mix A 17 x 13mm sized irregular shaped and heterogeneously enhancing mass is seen expanding the left anal sac. The right anal sac presents within normal limits.

SEX Two of the sacral lymph nodes are enlarged and measure 13 x 9mm each.

Female The left hypogastric lymph node is severely enlarged and measures 35 x 22mm. The right hypogastric lymph node presents within normal limits.

AGE The left medial iliac lymph node measures 10 x 6mm. The right medial iliac lymph node measures 9 x 5mm.

11 Years Moderate chronic lumbosacral disc protrusion is seen.

INTERPRETED BY Moderate spondyloses are seen within the caudal thoracic and cranial lumbar spine.

Nele Eley, DVM
 Dr. med. Vet. DipECVDI

COMPUTED TOMOGRAPHIC DIAGNOSIS

- HOSPITAL NAME**
- Left anal sac mass meeting neoplastic criteria – known to represent anal sac adenocarcinoma.
 - 2 moderately enlarged sacral lymph nodes.
 - 1 severely enlarged left hypogastric lymph node.
 - Moderate degenerative lumbosacral stenosis.
 - Multiple mild spondylosis deformans.

Animal Surgical Center

INTERPRETATION OF THE FINDINGS & FURTHER RECOMMENDATIONS

REFERRING VET The CT findings of the anal glands are compatible with left anal gland adenocarcinoma.

Dr. Infernuso

The multiple lymphadenomegaly within the hypogastrium suggests presence of metastatic disease to 2 sacral lymph nodes and the left hypogastric lymph node which should be considered in the surgical planning of this patient.

INVOICE

53020

DATE

7-21-22



PATIENT

Penny Wada

SPECIES

Canine

BREED

Pitbull Mix

SEX

Female

AGE

11 Years

INTERPRETED BY

Nele Eley, DVM
Dr. med. Vet. DipECVDI

HOSPITAL NAME

Animal Surgical
Center

REFERRING VET

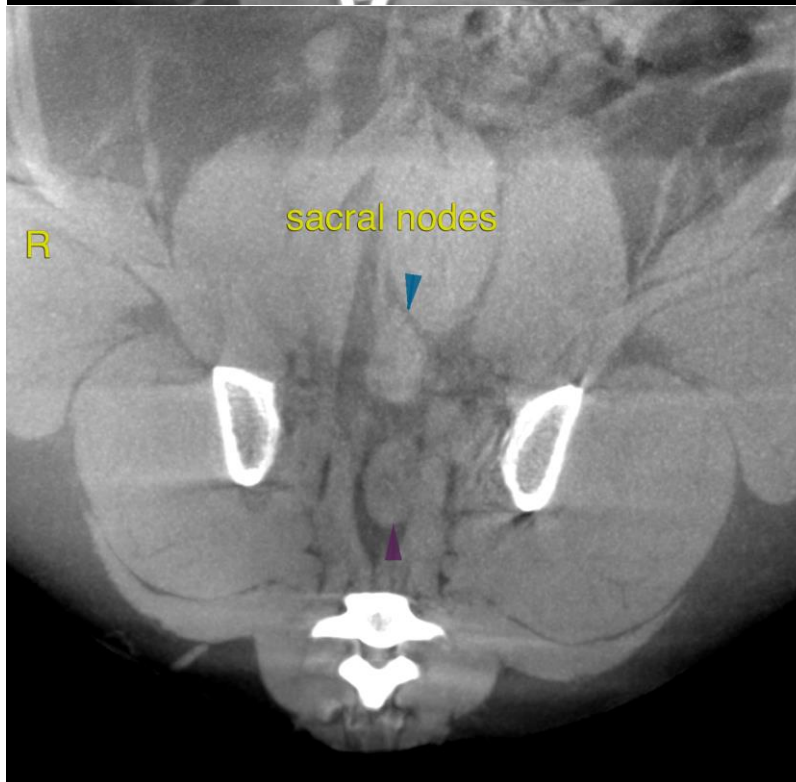
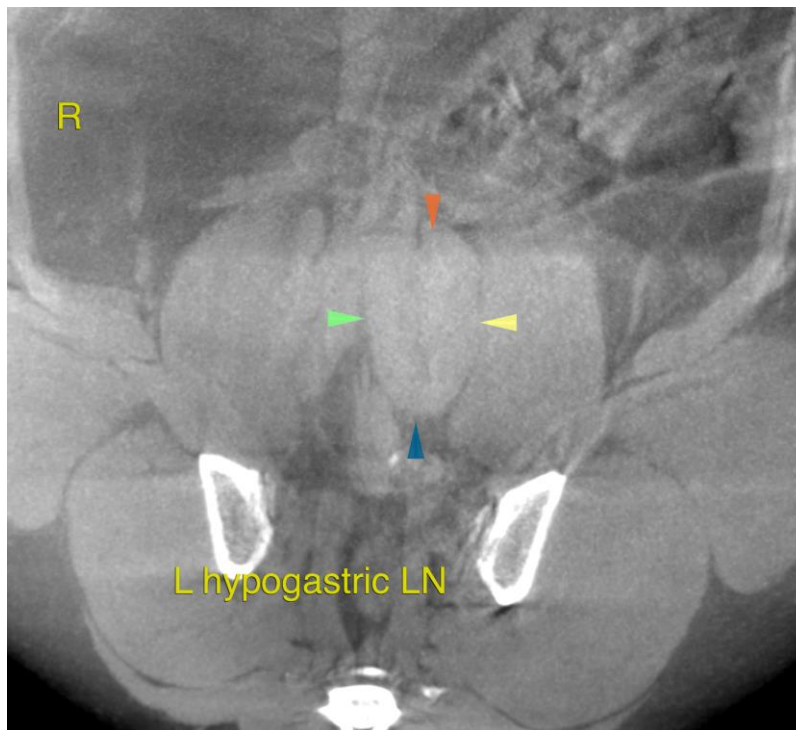
Dr. Inferuso

INVOICE

53020

DATE

7-21-22





PATIENT

Penny Wada

SPECIES

Canine

BREED

Pitbull Mix

SEX

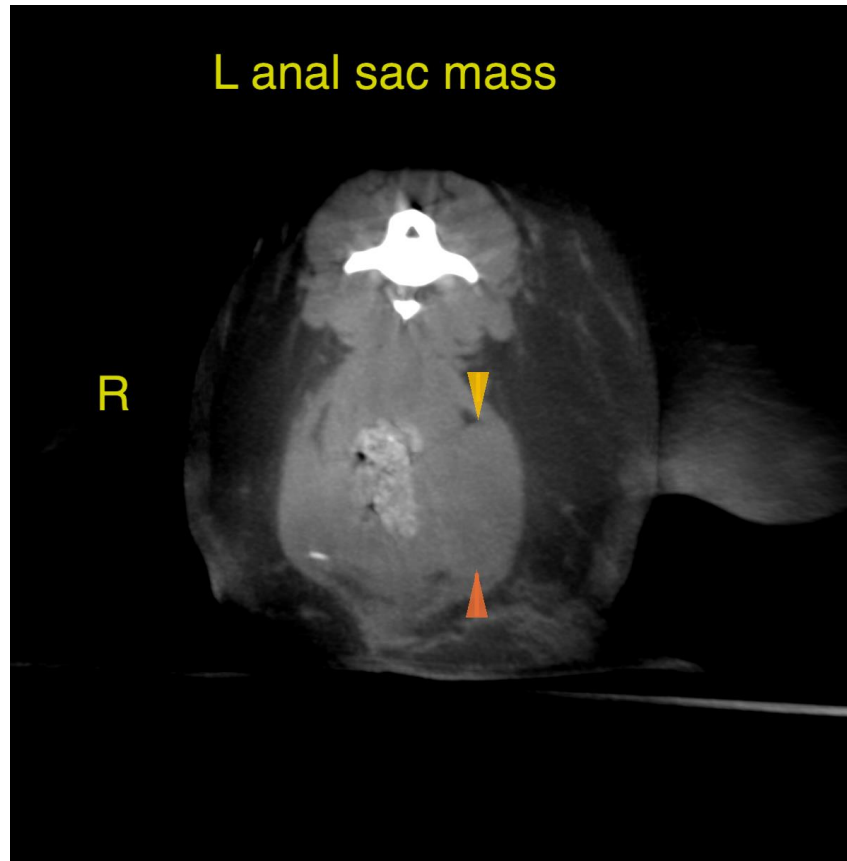
Female

AGE

11 Years

INTERPRETED BY

Nele Eley, DVM
Dr. med. Vet. DipECVDI



HOSPITAL NAME

Animal Surgical
Center

REFERRING VET

Dr. Inferuso

INVOICE

53020

DATE

7-21-22

The information and recommendations provided are based on the images presented by the referring veterinarian/sonographer. No evaluation can be communicated regarding pathology that was not visible in the image/video clips provided.

Thank you for this referral. If the clinical or image interpretation does not parallel your findings or if I can be of any further assistance please contact me.

Nele Eley, DVM, Dr. med. vet., DipECVDI
European Specialist in Veterinary Diagnostic Imaging, Cert. Radiology,
Senior lecturer University of Giessen, Germany, Veterinary Faculty, Department of Radiology
Nele.Eley@sonopath.com