



PATIENT PRESENTING CLINICAL SIGNS

PATIENT Franky Chuang
SPECIES Canine
BREED Terrier Mix
SEX NM
AGE 12 Years, 2 Months

Reason for Visit: ADR History: PET IS HERE FOR NOT DOING RIGHT SINCE LATE TUESDAY NIGHT/ OWNER STATES PET STARTED VOMITING MULTIPLE TIMES- FIRST FOOD THEN YELLOW FOAM LIKE BILE. OWNER STATES PET IS LETHARGIC AND NOT WANTING TO EAT, DRINK OR EVEN GET UP. LAST BM WAS NOTED TUESDAY AND APPEARED TO BE NORMAL. OWNER STATES NO PEOPLE FOOD OFFERED TO PET. PET DOES HAVE A PAST URINARY ISSUES AND IS ON C/D DIET

Abnormal PE/Chem/CBC/UA Results: Hydration: Appropriately hydrated Mentation: BAR EENT: No nasal discharge; nuclear sclerosis OU; clean no debris AU; No cough on tracheal palpation. Oral Cavity: moderate dental tartar present Lymph Nodes: Symmetrical, no changes in size, shape, consistency Skin: Good hair coat, no signs of ectoparasites. CV/Respiratory: No murmur or crackles/wheezing auscultated. Synchronous pulses. Normal bronchovesicular sounds. Tachycardic. Abd/GI: Painful on palpation of mid-abdomen Uro/Perineum: N Musculoskeletal: Ambulatory x4. BCS 5/9 Neurological: Appropriate Fecal: Diagnostic Testing Needed: abd rads, bloodwork Declined Diagnostics/Treatments: Findings: rads - decreased serosal detail mid abdomen [r/o pancreatitis vs mass effect] - consult pending CBC: suspec bands, Mono 1.22 (0.16-1.12), Eos 0.02 (0.06-1.23) Chem: ALT 147 (10-125), ALKP 932 (23-212), Lipase 5492 (200-1800), K 3.1 (3.5-5.8), Cl 104 (109-122) cPL: abnormal

RADIOGRAPHIC STUDY OF THE ABDOMEN

Right lateral and ventrodorsal views totaling 2 images available for review.

RADIOGRAPHIC FINDINGS

Significantly reduced serosal detail is seen in the mid abdomen caudal to the stomach. The greater curvature of the stomach is mildly pushed cranially. Moderate caudal deviation of the transverse colon is seen.

Three short linear mineral opacities are seen in the cranial abdomen and appear to be free within the mesentery.

Mild generalized hepatomegaly is seen.

Gastric aerophagia is noted.

INTERPRETED BY

Nele Eley, DVM
 Dr. med. Vet. DipECVDI

HOSPITAL NAME

DPC Veterinary Hospital

REFERRING VET

Dr. White

RADIOGRAPHIC DIAGNOSIS

- Mid abdominal reduced serosal detail with mass effect.
- Suspect wire type foreign material.
- Hepatomegaly.
- Gastric aerophagia.

INVOICE

53011

INTERPRETATION OF THE FINDINGS & FURTHER RECOMMENDATIONS

Based on the position and mass effect, pancreatopathy is most likely the cause of the radiographic changes. Consider pancreatitis, pancreatic abscess, pancreatic neoplasia, pancreatic pseudocyst, and other mesenteric pathology with regional peritonitis or necrosis potential differential diagnoses. Further definition by means of abdominal ultrasound is strongly recommended if not performed already.

DATE

7-21-22



PATIENT

The wire type foreign material is typically inert and not of clinical significance.

Franky Chuang

The mild hepatomegaly may be due to vacuolar or other degeneration. Metabolic or endocrine hepatopathy, hepatitis, and diffuse neoplastic infiltrate are other potential differential diagnoses. Correlate with the laboratory values and eventually with the abdominal ultrasound.

SPECIES

Canine

BREED

Terrier Mix

SEX

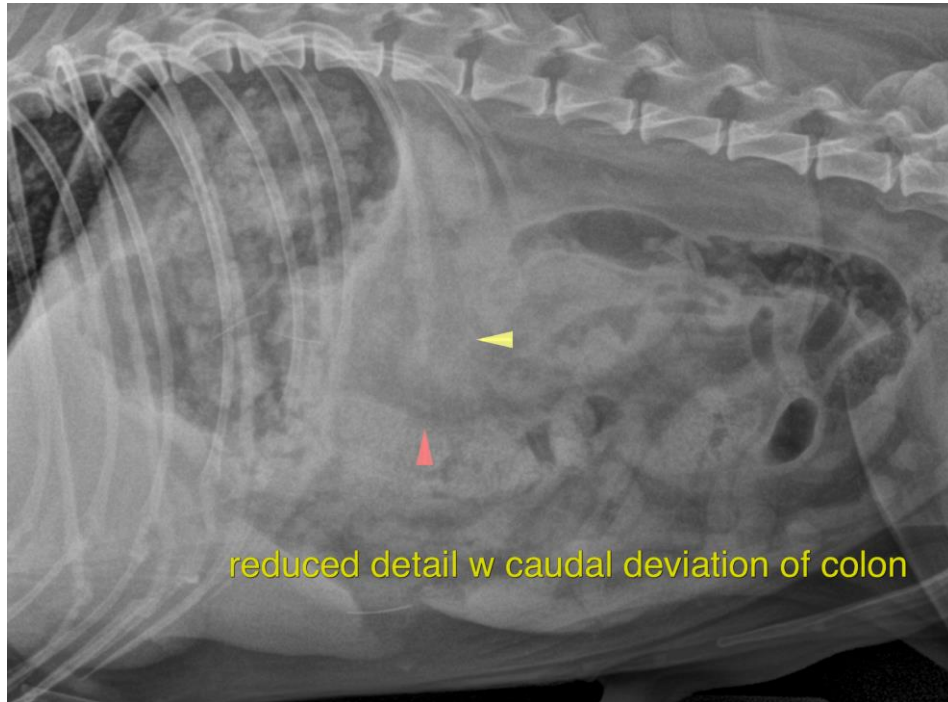
NM

AGE

12 Years, 2 Months

INTERPRETED BY

Nele Eley, DVM
Dr. med. Vet. DipECVDI



reduced detail w caudal deviation of colon

HOSPITAL NAME

DPC Veterinary
Hospital

The information and recommendations provided are based on the images presented by the referring veterinarian/sonographer. No evaluation can be communicated regarding pathology that was not visible in the image/video clips provided.

REFERRING VET

Dr. White

Thank you for this referral. If the clinical or image interpretation does not parallel your findings or if I can be of any further assistance please contact me.

Nele Eley, DVM, Dr. med. vet., DipECVDI
European Specialist in Veterinary Diagnostic Imaging, Cert. Radiology,
Senior lecturer University of Giessen, Germany, Veterinary Faculty, Department of Radiology
Nele.Eley@sonopath.com

INVOICE

53011

DATE

7-21-22