



PATIENT

Bubba De Prospo

PRESENTING CLINICAL SIGNS

Intermittent lameness left thoracic limb

SPECIES

Canine

RADIOGRAPHIC STUDY OF THE LEFT FRONT LIMB

Mediolateral views of the left shoulder, elbow, and carpus and craniocaudal/dorsopalmar view of the left elbow and carpus totaling 3 images available for review.

BREED

Pitbull

RADIOGRAPHIC FINDINGS

Left Shoulder

New bone formation is seen at the caudal aspect of the glenoid cavity and humeral head. There also is a moderate amount of new bone at the supraglenoid tubercle at the cranial margin of the glenoid cavity.

SEX

Male Neutered

Left Elbow

A small and smoothly delineated osteophyte is present on the proximal contour of the left anconeal process. No evidence of subchondral bone defects and no defect of the medial coronoid process are seen.

AGE

3 Years

The left and right carpus present within normal limits.

INTERPRETED BY

Nele Eley, DVM
Dr. med. Vet. DipECVDI

RADIOGRAPHIC DIAGNOSIS

- Moderate left shoulder osteoarthritis with enthesophytosis at the origin of the left biceps tendon.
- Mild left elbow osteoarthritis.
- Radiographically normal carpus.

HOSPITAL NAME

New Bridge
Veterinary Practice

INTERPRETATION OF THE FINDINGS & FURTHER RECOMMENDATIONS

The left shoulder presents moderate osteoarthritic changes. The new formation at the supraglenoid tubercle may simply represent osteophytosis, however, enthesophytes or avulsion at the origin of the biceps tendon are a potential differential diagnosis. Clinical correlation is required. In case of painful shoulder flexion or other clinical signs of shoulder pathology, further definition by means of ultrasound or an MRI could be considered.

REFERRING VET

Dr. Abina Glennon

The osteoarthritic changes of the left elbow are mild. No radiographic evidence of medial coronoid pathology or osteochondritis is seen. The mild osteophytosis may not necessarily be of clinical significance. Clinical correlation is required.

INVOICE

53014

DATE

7-21-22



PATIENT

Bubba De Prospo

SPECIES

Canine

BREED

Pitbull

SEX

Male Neutered

AGE

3 Years

INTERPRETED BY

Nele Eley, DVM
Dr. med. Vet. DipECVDI

HOSPITAL NAME

New Bridge
Veterinary Practice

REFERRING VET

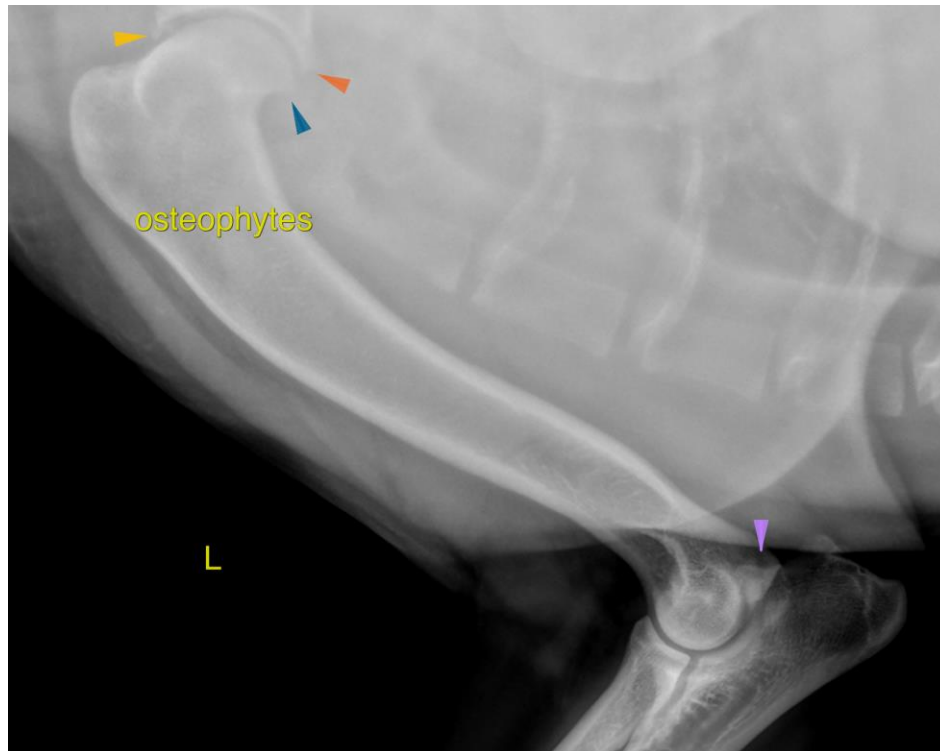
Dr. Abina Glennon

INVOICE

53014

DATE

7-21-22



The information and recommendations provided are based on the images presented by the referring veterinarian/sonographer. No evaluation can be communicated regarding pathology that was not visible in the image/video clips provided.

Thank you for this referral. If the clinical or image interpretation does not parallel your findings or if I can be of any further assistance please contact me.

Nele Eley, DVM, Dr. med. vet., DipECVDI
European Specialist in Veterinary Diagnostic Imaging, Cert. Radiology,
Senior lecturer University of Giessen, Germany, Veterinary Faculty, Department of Radiology
Nele.Eley@sonopath.com