



PATIENT PRESENTING CLINICAL SIGNS

Bam Parson Chronic reverse sneeze

COMPUTED TOMOGRAPHIC STUDY OF THE HEAD

SPECIES Plain and post contrast studies available for review.

Canine

COMPUTED TOMOGRAPHIC FINDINGS

BREED The brain presents no deviation from normal anatomy and symmetry. The grey and white matter distinction and the neuroparenchymal attenuation are as expected. The distribution of contrast enhancement is within normal limits throughout the parenchyma and meninges. The ventricular system is non-dilated and within the limits of the expected volume and symmetry.

Havanese

SEX Mild swelling of the mucosal lining of the turbinates is seen focally within both nasal cavities. There is no evidence of turbinate destruction, foreign material, or a soft tissue mass. No evidence of nasopharyngeal stenosis is seen.

Neutered Male

Both temporomandibular joints present congruent joint spaces with even subchondral bone surfaces and are considered within normal limits.

AGE

2 Years

Both tympanic bullae are aerated, the mucosal lining is not seen, the bony wall is smooth and thin. The external auditory meatuses present within normal limits.

INTERPRETED BY

Nele Eley (Ondreka),
DVM Dr. med. vet.,
DipECVDI

Mild bilateral medial retropharyngeal and submandibular lymphadenomegaly is noted. The short-to-long-axis ratios and contrast enhancement pattern of the lymph nodes are maintained.

The salivary glands present within normal limits.

The visible dentition is within normal limits.

HOSPITAL NAME

Mobile Pet Imaging

COMPUTED TOMOGRAPHIC DIAGNOSIS

- Mild bilateral nondestructive rhinitis.
- Mild bilaterally symmetric submandibular and medial retropharyngeal lymphadenomegaly.

INTERPRETATION OF FINDINGS & FURTHER RECOMMENDATIONS

REFERRING VET

Meaux

The CT findings suggest presence of bilateral nondestructive rhinitis with no evidence of foreign material, no signs of fungal rhinitis, and no evidence of neoplastic pathology. Consider lymphoplasmacytic or allergic inflammatory rhinitis versus infectious rhinitis such as viral, bacterial, and less likely parasitic. Rhinoscopy with sampling is recommended and has already been scheduled for further definition.

INVOICE

53010

DATE

7-21-22



PATIENT

Bam Parson

SPECIES

Canine

BREED

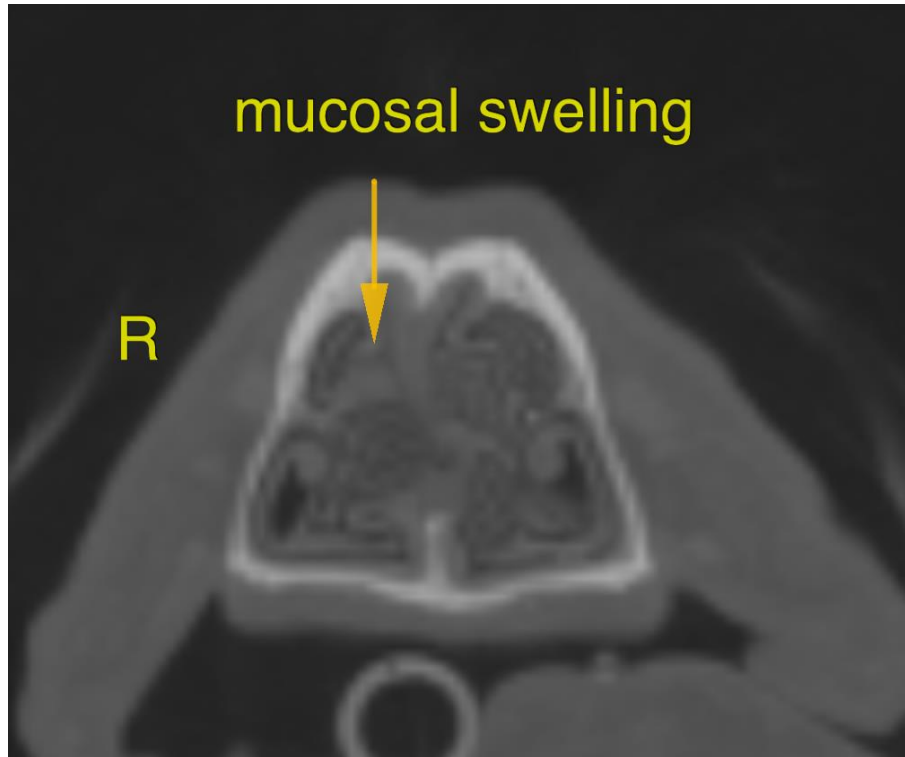
Havanese

SEX

Neutered Male

AGE

2 Years



INTERPRETED BY

Nele Eley (Ondreka),
DVM Dr. med. vet.,
DipECVDI

The information and recommendations provided are based on the images presented by the referring veterinarian. No evaluation can be communicated regarding pathology that was not visible in the image/video clips provided.

Thank you for this referral. If the clinical or image interpretation does not parallel your findings or if I can be of any further assistance please contact me.

HOSPITAL NAME

Mobile Pet Imaging

Nele Eley (Ondreka), DVM, Dr. med. vet., DipECVDI
European Specialist in Veterinary Diagnostic Imaging, Cert. Radiology,
Senior lecturer University of Giessen/Germany, Veterinary Faculty, Department of Radiology.
Nele.Eley@sonopath.com

REFERRING VET

Meaux

INVOICE

53010

DATE

7-21-22