

PATIENT PRESENTING CLINICAL SIGNS

Emmy Knox Dog has bilateral CCL rupture. Left worse than the right. TTA Sx on the left first and then the right in 8 weeks. Pre Sx MSK U/S

SPECIES Abnormal PE/Chem/CBC/UA Results: Positive cranial drawer, CTT, Medial buttress.

Canine **ULTRASONOGRAPHIC STUDY OF THE LEFT STIFLE**

BREED A large amount of anechoic effusion is seen within the supra- and infrapatellar recesses of the left stifle joint. There is a moderate amount of periarticular osteophytes. Moderate swelling of the synovium with synovial proliferations is noted.

Retriever x Rotti The cranial cruciate ligament presents as a broad stump of tissue of mixed echogenicity at the intercondylar eminence of the tibia, surrounded by a halo of hypoechoic tissue.

SEX The lateral meniscus is in situ, smoothly delineated and of uniform internal echoarchitecture. The caudal horn of the medial meniscus presents irregular outline with concave surface and part of the meniscal tissue appears to be missing and substituted by anechoic fluid.

Spayed Female

ULTRASONOGRAPHIC DIAGNOSIS

- Moderate to severe osteoarthritis of the left stifle joint with full rupture of the cranial cruciate ligament and suspect medial meniscal injury

INTERPRETATION OF FINDINGS & FURTHER RECOMMENDATIONS

INTERPRETED BY The ultrasonographic findings confirm the presence of complete rupture of the left cranial cruciate ligament. The findings furthermore suggest potential for a medial meniscal injury. Intervention including arthrotomy or arthroscopy is recommended in order to address the biomechanical instability of the joint and revise the joint for potential meniscal injury.

Nele Eley (Ondreka),
DVM Dr. med. vet.,
DipECVDI

HOSPITAL NAME

Westview Vet
Hospital

REFERRING VET

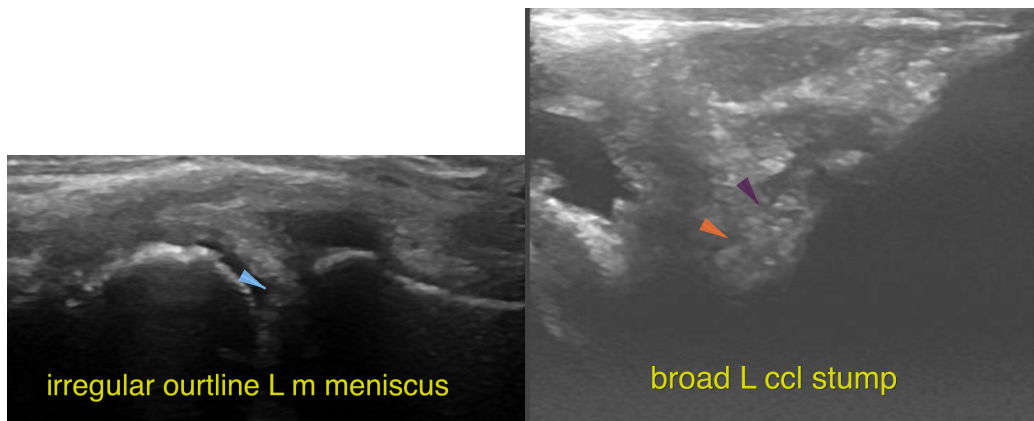
Dr. Brian J Barnes

INVOICE

44379

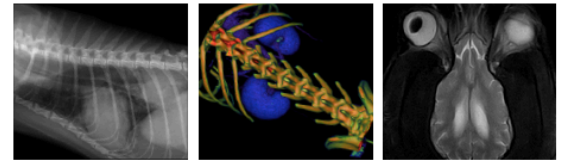
DATE

7/20/23



irregular outline L m meniscus

broad L ccl stump



PATIENT

Emmy Knox

The information and recommendations provided are based on the images presented by the referring veterinarian. No evaluation can be communicated regarding pathology that was not visible in the image/video clips provided.

SPECIES

Canine

Thank you for this referral. If the clinical or image interpretation does not parallel your findings or if I can be of any further assistance please contact me.

BREED

Retriever x Rotti

Nele Eley (Ondreka), DVM, Dr. med. vet., DipECVDI
European Specialist in Veterinary Diagnostic Imaging, Cert. Radiology,
Senior lecturer University of Giessen/Germany, Veterinary Faculty, Department of Radiology.
Nele.Eley@sonopath.com

SEX

Spayed Female

AGE

3 Years 3 Months

INTERPRETED BY

Nele Eley (Ondreka),
DVM Dr. med. vet.,
DipECVDI

HOSPITAL NAME

Westview Vet
Hospital

REFERRING VET

Dr. Brian J Barnes

INVOICE

44379

DATE

7/20/23