



PATIENT

Maggie Moore

PRESENTING CLINICAL SIGNS

Referred for CT due to a 3 week history of intermittent vocalization, kyphosis and hesitant ambulation

Abnormal PE/Chem/CBC/UA Results: ambulatory at the time of presentation, rigid gait, no placing or proprioceptive deficits.

SPECIES

Canine

COMPUTED TOMOGRAPHIC STUDY OF THE CERVICAL, THORACIC, & LUMBAR SPINE

Plain and post-IV contrast studies available for review.

BREED

Beagle

COMPUTED TOMOGRAPHIC FINDINGS

Extrusion of mineral attenuating intervertebral disc material is seen within the upper cervical spine emerging from the intervertebral disc space C2/3. The intervertebral disc space is moderately narrowed. Well delineated mineral attenuating material is seen within the ventral epidural space with mild cranial and moderate caudal migration. Approximately 20% of the vertebral canal's cross sectional area is occupied. Moderate dorsal deviation and ventral compression of the spinal cord are seen.

SEX

FS

AGE

3 Years

The intervertebral discs within the cervical, thoracic, and lumbar spine reveal varying degrees of mineralization in terms of chondroid intervertebral disc degeneration.

COMPUTED TOMOGRAPHIC DIAGNOSIS

- Moderately compressive intervertebral disc extrusion after chondroid disc degeneration within the upper cervical spine at C2/3.
- Multifocal chondroid disc degeneration.

INTERPRETED BY

Nele Eley, DVM
Dr. med. Vet. DipECVDI

INTERPRETATION OF THE FINDINGS & FURTHER RECOMMENDATIONS

Mild to moderate deviation and compression of the spinal cord secondary to intervertebral disc extrusion is seen in the upper cervical spine at C2/3. Surgical decompression could be considered depending on the duration, severity, and development of the patient's clinical signs.

HOSPITAL NAME

Healing Spirit Animal
Wellness

REFERRING VET

Kris Flores

INVOICE

52956

DATE

7-19-22



PATIENT

Maggie Moore

SPECIES

Canine

BREED

Beagle

SEX

FS

AGE

3 Years

INTERPRETED BY

Nele Eley, DVM
Dr. med. Vet. DipECVDI

HOSPITAL NAME

Healing Spirit Animal
Wellness

REFERRING VET

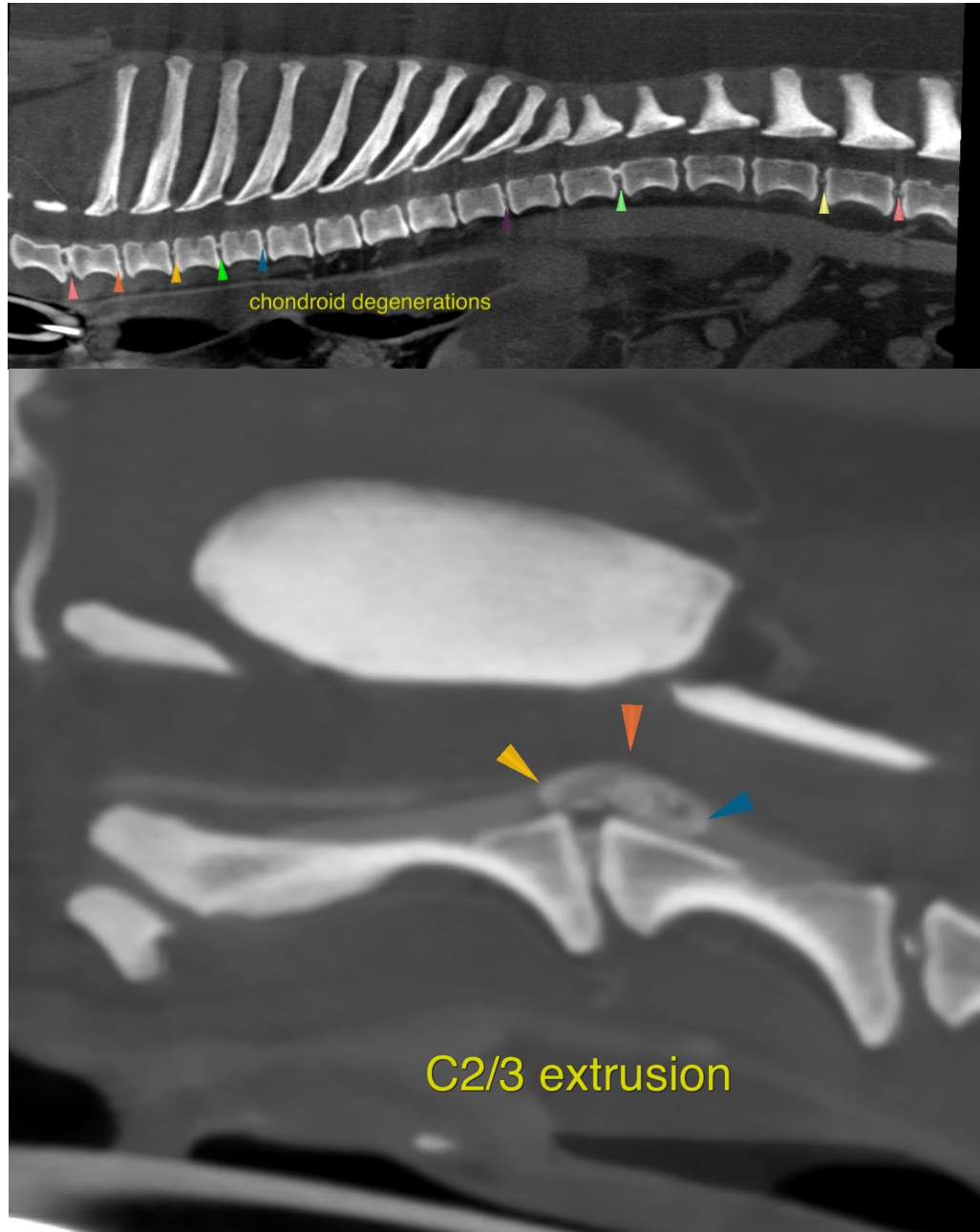
Kris Flores

INVOICE

52956

DATE

7-19-22





PATIENT

Maggie Moore

SPECIES

Canine

BREED

Beagle

SEX

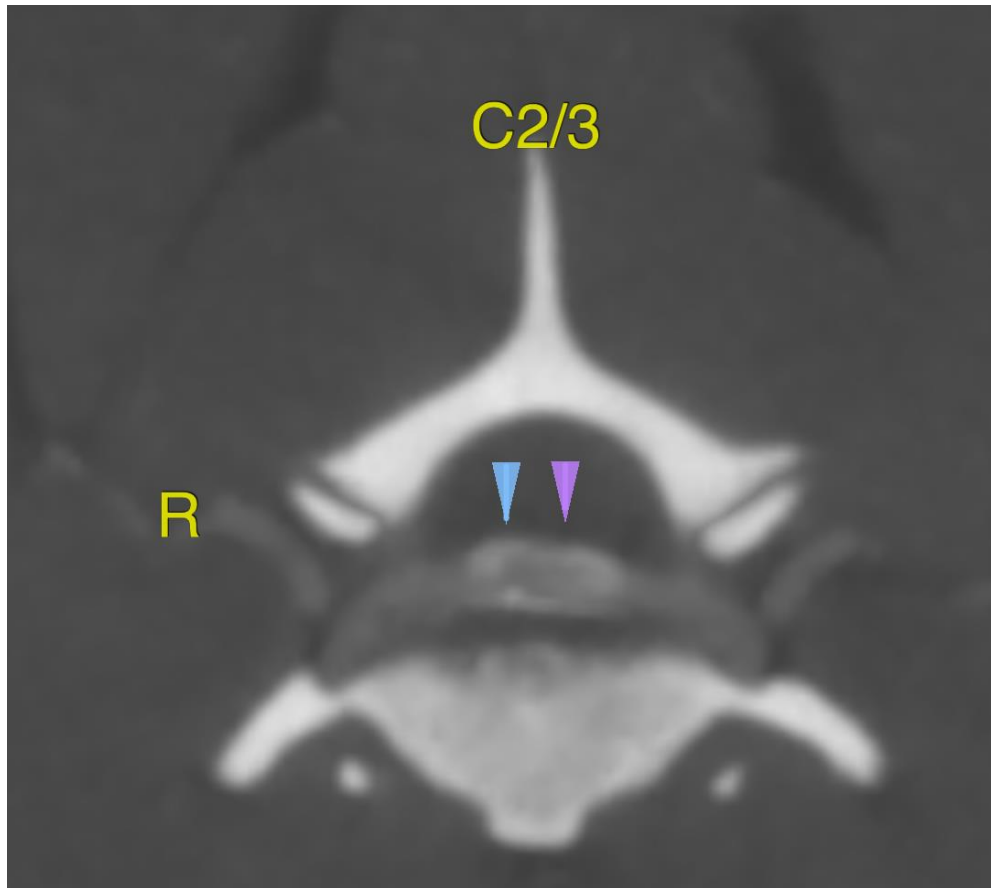
FS

AGE

3 Years

INTERPRETED BY

Nele Eley, DVM
Dr. med. Vet. DipECVDI



HOSPITAL NAME

Healing Spirit Animal
Wellness

REFERRING VET

Kris Flores

INVOICE

52956

DATE

7-19-22

The information and recommendations provided are based on the images presented by the referring veterinarian/sonographer. No evaluation can be communicated regarding pathology that was not visible in the image/video clips provided.

Thank you for this referral. If the clinical or image interpretation does not parallel your findings or if I can be of any further assistance please contact me.

Nele Eley, DVM, Dr. med. vet., DipECVDI
European Specialist in Veterinary Diagnostic Imaging, Cert. Radiology,
Senior lecturer University of Giessen, Germany, Veterinary Faculty, Department of Radiology
Nele.Eley@sonopath.com