



PATIENT

Jax Green

PRESENTING CLINICAL SIGNS

About 4 weeks ago he jumped off the bed and hurt his right back leg. He is still limping on it. Abnormal PE/Chem/CBC/UA Results: Ambulatory X 4 CREPITUS TO RIGHT HIND STIFLE, LUXATING PATELLA, DECREASED MUSCLE MASS

SPECIES

Canine

RADIOGRAPHIC STUDY OF THE STIFLES & PELVIS

Mediolateral and craniocaudal views of both stifles and ventrodorsal hip extended views of the pelvis totaling 6 images available for review.

BREED

Chihuahua
Longhaired

RADIOGRAPHIC FINDINGS

Stifles

Moderate articular swelling of the right stifle joint is noted. There is severe cranial thrust of the tibia. Mild periarticular osteophytosis accentuating the cranial margin of the tibia plateau, femoral trochlea, and distal pole of the patella is seen. The patella is in situ on the available images.

SEX

MN

Muscle atrophy of the right hind is noted

AGE

7 Years, 1 Month

The left stifle joint presents within age related normal limits.

Pelvis

Both coxofemoral joints present within the expected limits. No evidence of dysplasia, osteoarthritis, or other structural injury is seen.

INTERPRETED BY

Nele Eley, DVM
Dr. med. Vet. DipECVDI

RADIOGRAPHIC DIAGNOSIS

- Radiographic evidence of cranial cruciate ligament failure in the right stifle with mild to moderate osteoarthritic changes.
- Disuse atrophy of the right hind limb musculature.

HOSPITAL NAME

Elizabeth Animal
Hospital

INTERPRETATION OF THE FINDINGS & FURTHER RECOMMENDATIONS

The radiographic findings are compatible with presence of failure of the cranial cruciate ligament in the right stifle. Concurrent meniscopathy and patella luxation (grade 1 or 2) cannot be ruled out. The secondary osteoarthritic changes are mild to moderate at this point. Prolonged disuse of the right hind limb is indicated by the muscle atrophy.

REFERRING VET

Kim Allyn, DVM

Consider surgical intervention to address the presumed biomechanical instability of the cruciate ligament and potentially to address the reported patella luxation.

INVOICE

52971

DATE

7-19-22



PATIENT

Jax Green

SPECIES

Canine

BREED

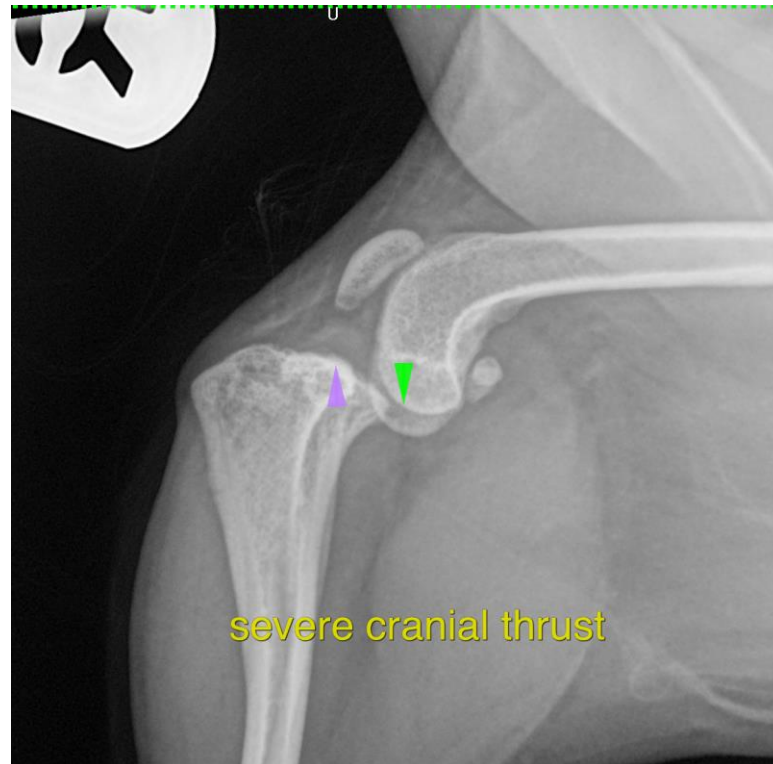
Chihuahua
Longhaired

SEX

MN

AGE

7 Years, 1 Month



INTERPRETED BY

Nele Eley, DVM
Dr. med. Vet. DipECVDI

The information and recommendations provided are based on the images presented by the referring veterinarian/sonographer. No evaluation can be communicated regarding pathology that was not visible in the image/video clips provided.

HOSPITAL NAME

Elizabeth Animal
Hospital

Thank you for this referral. If the clinical or image interpretation does not parallel your findings or if I can be of any further assistance please contact me.

Nele Eley, DVM, Dr. med. vet., DipECVDI
European Specialist in Veterinary Diagnostic Imaging, Cert. Radiology,
Senior lecturer University of Giessen, Germany, Veterinary Faculty, Department of Radiology
Nele.Eley@sonopath.com

REFERRING VET

Kim Allyn, DVM

INVOICE

52971

DATE

7-19-22