



PATIENT PRESENTING CLINICAL SIGNS

Lily Vatansever Diagnosed with suspected adrenal mass early 2021 and at the time the mass was invading the caudal vena cava and notable blood clots were appreciated in the vena cava, and was not a surgical candidate at the time. Pet has been on Palladia for the past 18 weeks and the tumor has decreased in size substantially and owner would like to see if performing surgery at this time is less risky.

SPECIES

Canine **COMPUTED TOMOGRAPHIC STUDY OF THE ABDOMEN & THORAX**

Plain and post contrast studies of the abdomen and post contrast study of the thorax available for review.

BREED

Dachshund **COMPUTED TOMOGRAPHIC FINDINGS**

Abdomen

SEX

Spayed Female A large irregular shaped and ill-defined mass is seen in the craniodorsal abdomen. The mass measures approximately 12 cm in length, 10 cm in width, and 6 cm in height. The mass effect onto the surrounding abdominal organs is severe. The mass encompasses the abdominal aorta and grows into as well as circumferential to the caudal vena cava. Severe compression and infiltration of the caudal vena cava with multiple intratumoral vascular anastomoses is seen which appear to bridge the post- and pre- tumoral caudal vena cava. The right kidney, right adrenal, and left adrenal gland cannot be seen separate from the mass. Moderate pyelectasia of the left kidney is seen and part of the left ureter appears to be involved in the mass.

AGE

15 Years, 5 Months

INTERPRETED BY

Nele Eley (Ondreka),
DVM Dr. med. vet.,
DipECVDI

Occasional hypoenhancing splenic nodules are present.
The liver and gallbladder present within age related normal limits.
Occasional chondroid disc degeneration is seen.

Thorax

HOSPITAL NAME

Mobile Pet Imaging

The bony and surrounding soft tissue structures are within normal limits.
The sternal, cranial mediastinal and tracheobronchial lymph nodes are small elongated with a normal short-to-long-axis-ratio is < 0.5, the attenuation and contrast enhancement pattern are uniform and considered within normal limits.

REFERRING VET

Meaux

The cardiovascular structures including the pulmonary vasculature are within normal limits.
The bronchial tree presents with regular branching and tapers uniformly towards the periphery as expected, the bronchial walls are thin and smooth. The bronchus-to-artery ratio is within normal limits.

INVOICE

52934

The lung parenchyma presents the expected architecture and attenuation behavior.
Small incidental gas pockets are seen within the esophageal lumen, there is no evidence of abnormal dilation.

DATE

7-18-22



PATIENT COMPUTED TOMOGRAPHIC DIAGNOSIS

Lily Vatansever

- Large retroperitoneal soft tissue mass with aggressive biological behavior and severe intravascular and vasculocentric growth affecting the caudal vena cava and abdominal aorta; suspect left ureteral involvement with partial obstruction and moderate left renal pyelectasia.

SPECIES

- Splenic nodules.
- No evidence of pulmonary metastatic disease.

Canine

INTERPRETATION OF FINDINGS & FURTHER RECOMMENDATIONS

BREED

Dachshund

The CT findings are compatible with the history of right adrenal gland mass. The mass at this point appears to involve both the right and left adrenal glands. Extensive intravascular growth of the tumor inside and circumferential to the caudal vena cava is seen. The pathway of the abdominal caudal vena cava is discontinuous level with the mass and appears to be bridged by multiple upstream venovenous anastomoses. The mass also encompasses the abdominal aorta. Absence of the right kidney may be due to hypoplasia/aplasia and less likely tumorous infiltrate. Pheochromocytoma is a primary differential diagnosis with the pertinent CT findings. However, adenocarcinoma and other retroperitoneal neoplasia cannot be ruled out entirely. Unfortunately, the mass is nonresectable.

SEX

Spayed Female

AGE

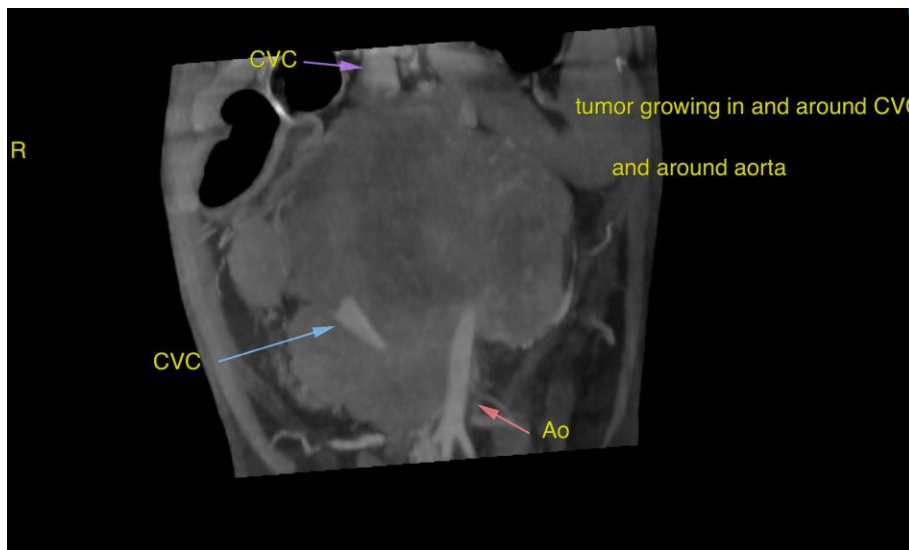
15 Years, 5 Months

INTERPRETED BY

Nele Eley (Ondreka),
DVM Dr. med. vet.,
DipECVDI

HOSPITAL NAME

Mobile Pet Imaging



REFERRING VET

Meaux

The information and recommendations provided are based on the images presented by the referring veterinarian. No evaluation can be communicated regarding pathology that was not visible in the image/video clips provided.

INVOICE

52934

Thank you for this referral. If the clinical or image interpretation does not parallel your findings or if I can be of any further assistance please contact me.

DATE

7-18-22

Nele Eley (Ondreka), DVM, Dr. med. vet., DipECVDI
European Specialist in Veterinary Diagnostic Imaging, Cert. Radiology,
Senior lecturer University of Giessen/Germany, Veterinary Faculty, Department of Radiology.
Nele.Eley@sonopath.com