



PATIENT

Gunner Tennen

PRESENTING CLINICAL SIGNS

Hind left leg lameness.

SPECIES

Canine

ULTRASONOGRAPHIC FINDINGS

Left Stifle

Moderate anechoic effusion is seen in the supra- and infra-patellar recesses of the left stifle joint. There is moderate thickening of the synovium. The cranial cruciate ligament is continuous yet presents thickened and ill-defined. Infrapatellar fat pad cyst formations are seen. The medial meniscus is in situ and presents no deviation from its expected anatomy.

BREED

Lab

Right Stifle

SEX

MN

Scant effusion is seen in the suprapatellar recess of the right stifle joint. There is no evidence of synovial or capsular thickening or proliferation. The cranial cruciate ligament appears to be continuous and well-delineated, no deviation from normal echoarchitecture is noted. Lateral and medial menisci are within their anticipated positions and align well below the bone surfaces, meniscal surfaces are even and smooth. The echotexture is hypo echoic and uniform. The joint margins are smooth, no osteophytes are seen. The infra patellar fat pad present, the expected echo architecture.

AGE

7 Years

ULTRASONOGRAPHIC DIAGNOSIS

- Left stifle osteoarthritis with cranial cruciate ligament injury.
- Normal ultrasonographic presentation of the right stifle.

INTERPRETED BY

Nele Eley, DVM
Dr. med. Vet. DipECVDI

INTERPRETATION OF THE FINDINGS & FURTHER RECOMMENDATIONS

The findings of the left cranial cruciate ligament suggests partial rupture. Moderate synovialitis and effusion are seen concurrently. There is no evidence of meniscopathy at this point.

HOSPITAL NAME

All Creatures Great
and Small Denville

The mild effusion within the right stifle may be an expression of early degenerative joint disease, however, prior exercise or manipulation can be potential sources of mild effusion as well.

REFERRING VET

Dr. Mitrovic

INVOICE

59400

DATE

7-17-23



PATIENT

Gunner Tennen

SPECIES

Canine

BREED

Lab

SEX

MN

AGE

7 Years

INTERPRETED BY

Nele Eley, DVM
Dr. med. Vet. DipECVDI

HOSPITAL NAME

All Creatures Great
and Small Denville

REFERRING VET

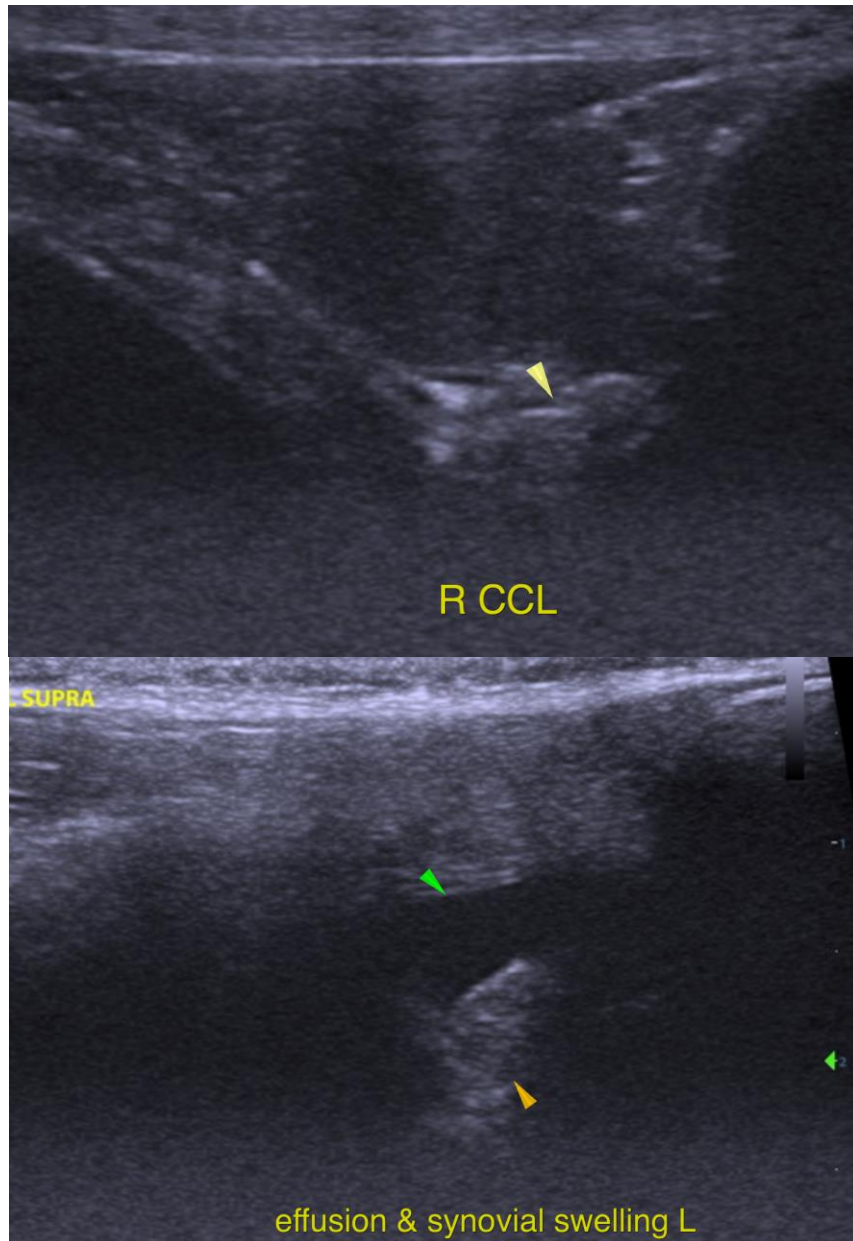
Dr. Mitrovic

INVOICE

59400

DATE

7-17-23





PATIENT

Gunner Tennen

SPECIES

Canine

BREED

Lab

SEX

MN

AGE

7 Years

INTERPRETED BY

Nele Eley, DVM
Dr. med. Vet. DipECVDI

HOSPITAL NAME

All Creatures Great
and Small Denville

REFERRING VET

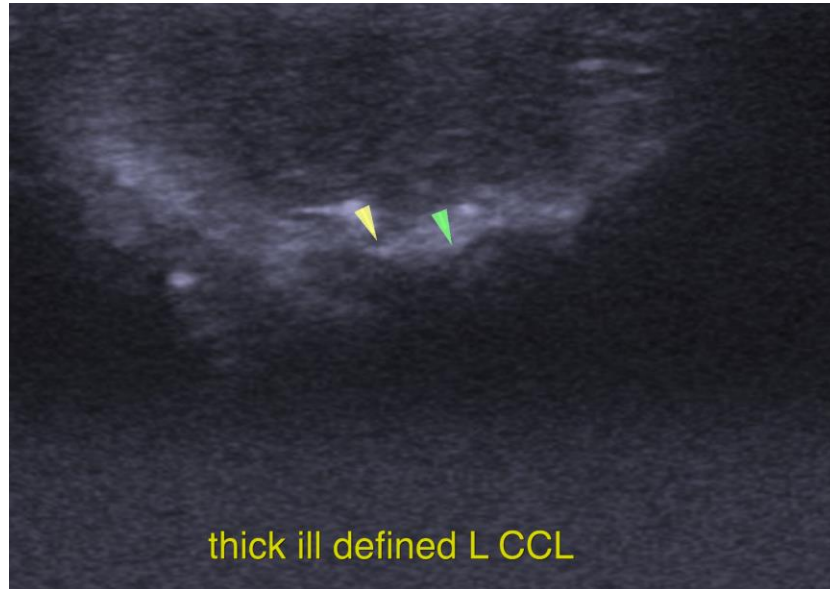
Dr. Mitrovic

INVOICE

59400

DATE

7-17-23



The information and recommendations provided are based on the images presented by the referring veterinarian/sonographer. No evaluation can be communicated regarding pathology that was not visible in the image/video clips provided.

Thank you for this referral. If the clinical or image interpretation does not parallel your findings or if I can be of any further assistance please contact me.

Nele Eley, DVM, Dr. med. vet., DipECVDI
European Specialist in Veterinary Diagnostic Imaging, Cert. Radiology,
Senior lecturer University of Giessen, Germany, Veterinary Faculty, Department of Radiology
info@sonopath.com