



**PATIENT**

Rocky Irizarry

**PRESENTING CLINICAL SIGNS**

ultrasound submitted to sonopath on 7/12/22 recc. ct to asses right adrenal mass.

**SPECIES**

Canine

**COMPUTED TOMOGRAPHIC STUDY OF THE ABDOMEN**

Plain and post contrast studies available for review.

**BREED**

Pomeranian

**COMPUTED TOMOGRAPHIC FINDINGS**

The serosal fat presents normal attenuation behavior. There is no evidence of peritoneal effusion or peritonitis.

**SEX**

CM

Multiple small cortical renal cysts are seen in both kidneys. The pyelogram presents within normal limits.

A 2.2 x 1.5 x 1.4 cm sized irregular shaped and ill-defined right adrenal gland mass with multifocal mineralization and heterogeneous contrast enhancement is seen. The mass causes moderate regional compression of the caudal vena cava. The right phrenicoabdominal vein is obliterated. No direct invasion of the caudal vena cava or right renal vein are seen. The left adrenal gland presents within the expected limits.

**AGE**

11 Years

Small splenic nodules of variable enhancement and up to 1.0 cm diameter are present.

**INTERPRETED BY**

Nele Eley, DVM  
Dr. med. Vet. DipECVDI

The liver presents moderate generalized enlargement with mildly rounded lobar margins and diffusely heterogeneous contrast enhancement.

The gallbladder is severely distended. A mild amount of hyperattenuating material is seen within the gallbladder as well as one 2mm sized calculus. No evidence of cystic or common bile duct obstruction.

**HOSPITAL NAME**

Animal Clinic of  
Queens

The pancreas is evenly contoured, the pancreatic parenchyma is homogeneous and presents uniform contrast enhancement.

The position, delineation, wall and content of the gastrointestinal tract are considered within normal limits throughout.

**REFERRING VET**

Dr Piotr Kwasnik

Multiple spondyloses are seen throughout the lumbar spine and thoracolumbar junction.

**COMPUTED TOMOGRAPHIC DIAGNOSIS**

**INVOICE**

52912

- Right adrenal gland mass with mineralizations meeting neoplastic criteria - potential for early vascular invasion of the right adrenal gland mass.
- Hepatopathy with hepatomegaly and heterogeneous enhancement.
- Biliary microlithiasis and gallbladder sludge.
- Multiple splenic nodules.
- Multiple bilateral cortical renal cysts - likely degenerative.

**DATE**

7-16-22



**PATIENT INTERPRETATION OF THE FINDINGS & FURTHER RECOMMENDATIONS**

Rocky Irizarry

Primary differential diagnoses for the right adrenal gland mass are functional and nonfunctional adenocarcinoma. The CT findings suggest potential for early vascular invasion into the phrenicoabdominal vein. No invasion of the caudal vena cava is seen at this point. The odds of adenoma and pheochromocytoma are considered lower based on the CT findings of the adrenal glands and liver.

**SPECIES**

Canine

Differential diagnosis for the hepatic changes includes endocrine and metabolic hepatopathy as primary differential diagnoses. Diffuse inflammatory/infectious or neoplastic infiltrates cannot be ruled out entirely but appear rather unlikely based on the pertinent CT changes.

**BREED**

Pomeranian

The splenic nodules are compatible with benign nodular hyperplasia. Metastatic disease can never be ruled out entirely but appears less likely.

**SEX**

CM

**AGE**

11 Years

**INTERPRETED BY**

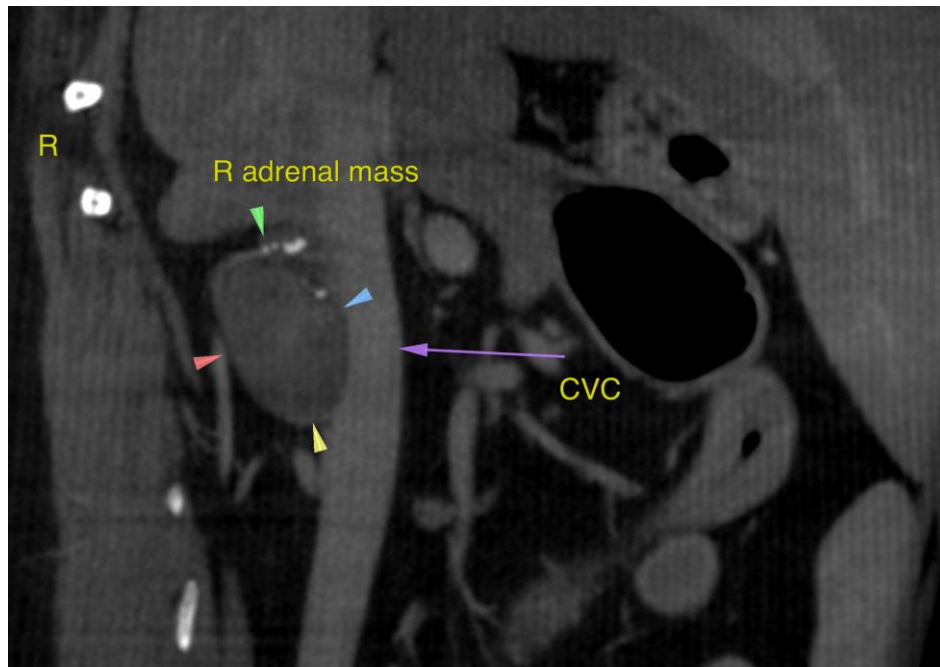
Nele Eley, DVM  
Dr. med. Vet. DipECVDI

**HOSPITAL NAME**

Animal Clinic of  
Queens

**REFERRING VET**

Dr Piotr Kwasnik



The information and recommendations provided are based on the images presented by the referring veterinarian/sonographer. No evaluation can be communicated regarding pathology that was not visible in the image/video clips provided.

**INVOICE**

52912

Thank you for this referral. If the clinical or image interpretation does not parallel your findings or if I can be of any further assistance please contact me.

**DATE**

7-16-22

**Nele Eley, DVM, Dr. med. vet., DipECVDI**  
European Specialist in Veterinary Diagnostic Imaging, Cert. Radiology,  
Senior lecturer University of Giessen, Germany, Veterinary Faculty, Department of Radiology  
Nele.Eley@sonopath.com