



**PATIENT PRESENTING CLINICAL SIGNS**

Mochi Lee Reason for Visit: URINARY ISSUE History: P HAS BEEN LEAKING URINE GOING ON SEVERAL MONTHS GETTING MORE FREQUENT AND LARGER AMOUNTS. O STATES P NORMALLY URINATES A LITTLE WHEN GETS EXCITED BUT O FEELS P NOT AWARE OF URINATING WILL HAPPEN WHEREVER SHE HAS BEEN LAYING/SLEEPING. O NOTICING BLOOD TINGED URINE SPOTS AFTER P HAS URINATED O STATES HAS HAPPENED BEFORE BUT GOES AWAY. NO ABNORMAL ODOR. NO OTHER CONCERNS.

**SPECIES**

Canine

**BREED**

Corgie

**SEX**

SF

Abnormal PE/Chem/CBC/UA Results: Hydration: Appropriately hydrated Mentation: BAR EENT: No nasal discharge; clear no discharge OU; clean no debris AU; No cough on tracheal palpation. Oral Cavity: Mild dental tartar present Lymph Nodes: Symmetrical, no changes in size, shape, consistency Skin: Good hair coat, no signs of ectoparasites. No lesions noted. CV/Respiratory: No murmur or crackles/wheezing auscultated. Synchronous pulses, normal rate. Normal bronchovesicular sounds. Abd/GI: Soft non painful abdomen, no organomegaly, no abnormalities on abdominal palpation Uro/Perineum: Severely hooded vulva, dark brown colored fur surrounding vulva Musculoskeletal: Ambulatory x4, no lameness noted. No pain on palpation of limbs. BCS 7/9 Neurological: Appropriate Diagnostic Testing Needed: Urinalysis, urine culture, abdominal radiographs, abdominal ultrasound Declined Diagnostics/Treatments: n/a Findings: - Urinalysis: USG 1.029, blood 50 Ery/uL

**AGE**

5 Years, 7 Months

**RADIOGRAPHIC STUDY OF THE ABDOMEN**

Right lateral and ventrodorsal views totaling 2 images available for review.

**RADIOGRAPHIC FINDINGS**

The patient is obese.

The surrounding bony structures are within normal limits.

No abnormalities of the extraabdominal soft tissues are noted. The abdominal wall is smooth and thin.

The serosal detail is maintained throughout the peritoneal and retroperitoneal space.

The liver is appropriate in position, size and presents uniform opacity.

The splenic head is in the anticipated position and within normal limits for size and opacity. The splenic body and tail are considered normal for position, size, shape and opacity.

Both kidneys are seen and present with normal size, shape, delineation and opacity. The urinary bladder is moderately distended. No abnormal opacities are seen associated with the urinary bladder. The position of the urinary bladder is prepelvic and considered within normal limits.

The stomach is in its anticipated position and presents normal content.

The small intestinal loops are of even diameter and non-dilated, a small amount of gas is seen within the small intestinal loops and considered within normal limits.

The colon is seen in the expected position and presents with appropriate content.

**INTERPRETED BY**

Nele Eley, DVM  
Dr. med. Vet. DipECVDI

**HOSPITAL NAME**

DPC Veterinary  
Hospital

**REFERRING VET**

Dr. Orcutt

**INVOICE**

52913

**DATE**

7-16-22



**PATIENT**

Mochi Lee

**RADIOGRAPHIC DIAGNOSIS**

- Normal radiographic findings of the abdomen.

**SPECIES**

Canine

**INTERPRETATION OF THE FINDINGS & FURTHER RECOMMENDATIONS**

The abdominal cavity including the kidneys and urinary bladder present within normal limits on the current radiographic study. Differential diagnosis includes lower urinary tract infection, congenital abnormality such as ureteral ectopia, or urocele, incontinence as long term complication after spay, urinary bladder dyssynergia, and other neurologic as well as hormonal issues.

**BREED**

Corgie

**SEX**

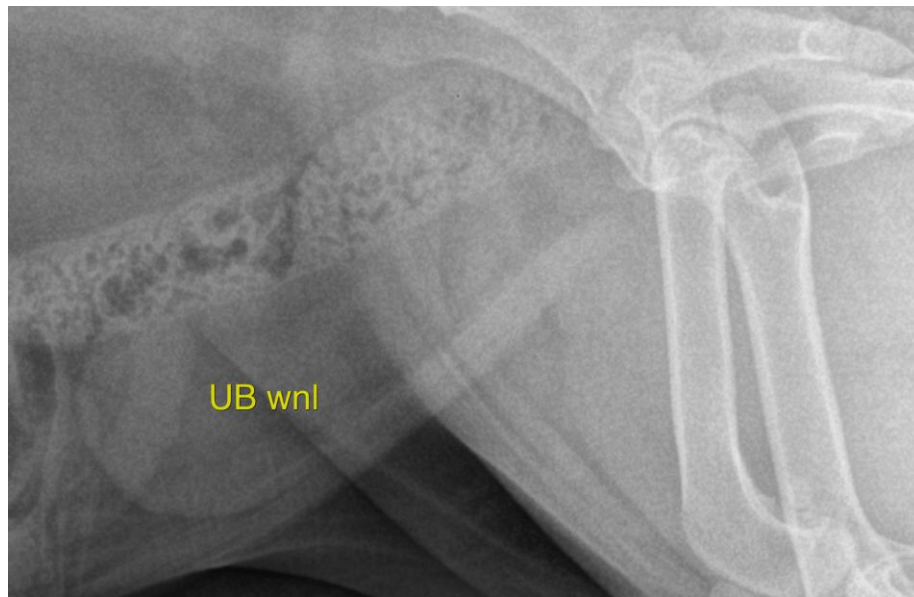
SF

**AGE**

5 Years, 7 Months

**INTERPRETED BY**

Nele Eley, DVM  
Dr. med. Vet. DipECVDI



**HOSPITAL NAME**

DPC Veterinary  
Hospital

**The information and recommendations provided are based on the images presented by the referring veterinarian/sonographer. No evaluation can be communicated regarding pathology that was not visible in the image/video clips provided.**

**REFERRING VET**

Dr. Orcutt

Thank you for this referral. If the clinical or image interpretation does not parallel your findings or if I can be of any further assistance please contact me.

**INVOICE**

52913

**Nele Eley, DVM, Dr. med. vet., DipECVDI**  
European Specialist in Veterinary Diagnostic Imaging, Cert. Radiology,  
Senior lecturer University of Giessen, Germany, Veterinary Faculty, Department of Radiology  
Nele.Eley@sonopath.com

**DATE**

7-16-22