

**PATIENT**

Izzy Carpenter

PRESENTING CLINICAL SIGNS

Persistent mild swelling at digit 5, right front paw. Left foot provided for comparison.

SPECIES

Canine

COMPUTED TOMOGRAPHIC STUDY OF THE FRONT PAWS

Plain studies available for review.

BREED

Shar Pei Mix

COMPUTED TOMOGRAPHIC FINDINGS

In the study labeled as the right front paw, mild soft tissue swelling of the digital pad of the 5th digit is seen accentuated in the palmar and medial interdigital area of this digit. There is no evidence of foreign material within the swollen soft tissue. The distal, middle, and proximal phalanges of the affected digit present within normal limits. No evidence of aggressive osteolytic changes is seen.

SEX

FS

A multipartite axial metacarpophalangeal sesamoid bone of the 4th and 5th digits is seen in the left front paw. The metacarpophalangeal joint of the 4th digit presents moderate osteoarthritic changes.

AGE

5 Years, 9 Months

COMPUTED TOMOGRAPHIC DIAGNOSIS

- Soft tissue swelling of the 5th digit's toe pad in the right front paw accentuated in the interdigital area.
- Normal CT findings of the bones in the right front paw.
- Multipartite sesamoid bones and metacarpophalangeal osteoarthritis of the 4th and 5th digits in the left front paw.

INTERPRETED BYNele Eley, DVM
Dr. med. Vet. DipECVDI**INTERPRETATION OF THE FINDINGS & FURTHER RECOMMENDATIONS**

Unspecific soft tissue swelling representing edema, hematoma, inflammation, infection, and less likely early infiltrative disease is seen in the distopalmar aspect of the 5th digit in the right front paw. No attenuating foreign material can be identified. Trauma and perforating injury with or without foreign material are the most common and likely underlying causes of the pertinent changes; however, dermatopathies and early infiltrative disease cannot be ruled out entirely. Correlate with the clinical inspection and consider sampling for further definition.

HOSPITAL NAMEAggie Animal Dental
Center**REFERRING VET**

Dr. Milinda Lommer

INVOICE

52897

DATE

7-14-22



PATIENT

Izzy Carpenter

SPECIES

Canine

BREED

Shar Pei Mix

SEX

FS

AGE

5 Years, 9 Months

INTERPRETED BY

Nele Eley, DVM
Dr. med. Vet. DipECVDI

HOSPITAL NAME

Aggie Animal Dental
Center

REFERRING VET

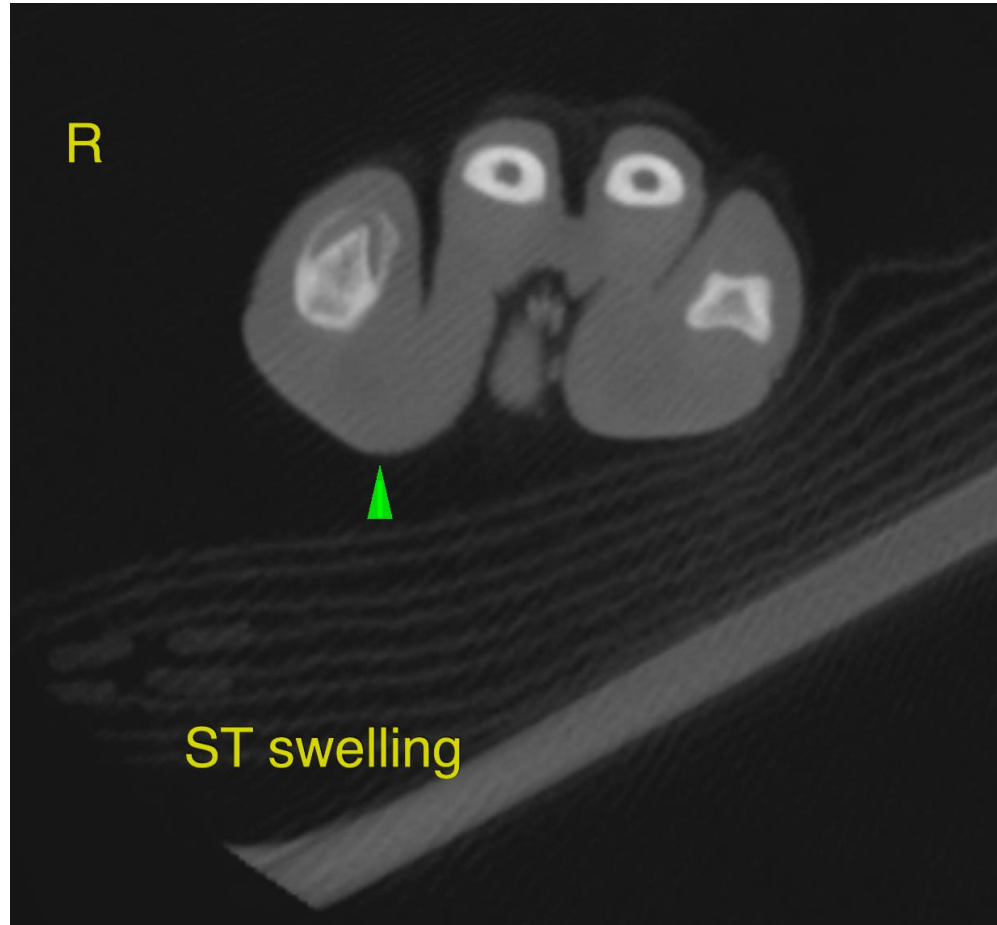
Dr. Milinda Lommer

INVOICE

52897

DATE

7-14-22



The information and recommendations provided are based on the images presented by the referring veterinarian/sonographer. No evaluation can be communicated regarding pathology that was not visible in the image/video clips provided.

Thank you for this referral. If the clinical or image interpretation does not parallel your findings or if I can be of any further assistance please contact me.

Nele Eley, DVM, Dr. med. vet., DipECVDI
European Specialist in Veterinary Diagnostic Imaging, Cert. Radiology,
Senior lecturer University of Giessen, Germany, Veterinary Faculty, Department of Radiology
Nele.Eley@sonopath.com