



PATIENT PRESENTING CLINICAL SIGNS

Reggie Sudol Rectal mass, looking for metastasis

COMPUTED TOMOGRAPHIC STUDY OF THE ABDOMEN & PELVIS

SPECIES

Canine

Plain and post contrast studies are available for review.

COMPUTED TOMOGRAPHIC FINDINGS

BREED

Border Collie

The serosal fat presents normal attenuation behavior. There is no evidence of peritoneal effusion or peritonitis.

Both kidneys present within normal limits for size, shape and organ architecture. After contrast administration a bilaterally symmetric and uniform nephro- and pyelogram is noted.

SEX

Male

The adrenal glands are within normal limits for size, shape and organ architecture.

Both liver and spleen present with normal shape, even surface, uniformly attenuating parenchyma and homogeneous contrast enhancement, unremarkable.

AGE

6 Years, 8 Months

The pancreas is evenly contoured, the pancreatic parenchyma is homogeneous and presents uniform contrast enhancement.

The position, delineation, wall and content of the gastrointestinal tract are considered within normal limits throughout.

INTERPRETED BY

Nele Eley (Ondreka),
DVM Dr. med. vet.,
DipECVDI

A 15mm sized soft tissue attenuating nodule with heterogeneous enhancement is seen in the perianal soft tissue in a 2 o'clock position. This nodule appears to be outside of the rectum and anal sphincter as well as outside of the anal sac. I am unable to identify additional rectal masses but there may be border effacement with the fecal matter in the rectum and descending colon.

HOSPITAL NAME

Mobile Pet Imaging

The hypogastric and medial iliac lymph nodes present within normal limits.

Moderate symmetric enlargement of the prostate with multiple small intraparenchymal cysts is seen. The prostate measures 4.5 x 3.5 x 3 cm.

REFERRING VET

Ciruta

The testicles present within normal limits.

Moderate degenerative lumbosacral stenosis with spondylosis deformans is noted.

COMPUTED TOMOGRAPHIC DIAGNOSIS

INVOICE

59352

- Left hand sided perianal nodule meeting neoplastic criteria.
- Moderate symmetric prostatomegaly with multiple cysts.
- No evidence of sublumbar lymphadenomegaly.
- Moderate degenerative lumbosacral stenosis.

DATE

7-13-23


PATIENT INTERPRETATION OF FINDINGS & FURTHER RECOMMENDATIONS

Reggie Sudol A mass within the rectum cannot be identified. See above. There is a 15mm sized perianal nodule in the left dorsal aspect of the perianal soft tissues. Differential diagnosis includes adenoma, adenocarcinoma, mast cell tumor, soft tissue sarcoma, and other. Final diagnosis will require sampling. FNA is recommended for further definition if not performed already.

SPECIES

Canine The findings of the prostate are compatible with benign prostatic hyperplasia of the non-neutered male. Prostatitis is a potential differential diagnosis. Prostatic neoplasia is highly unlikely.

BREED

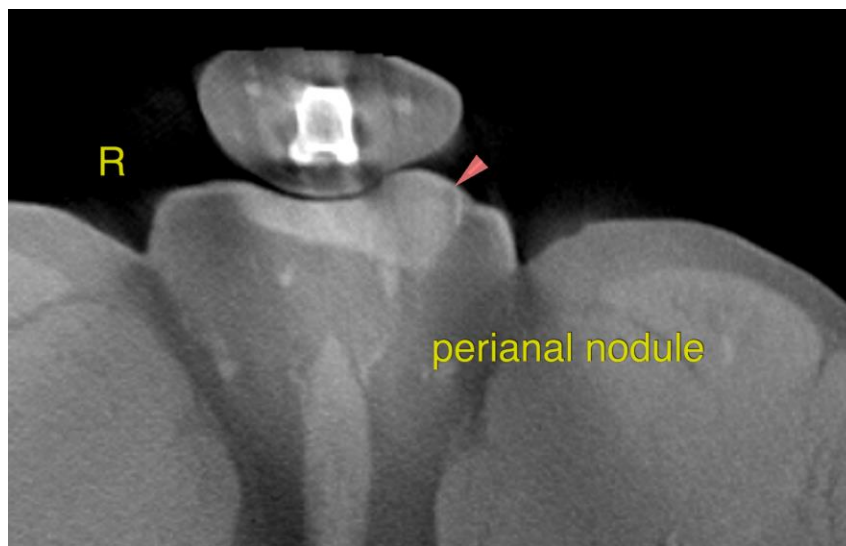
Border Collie

SEX

Male

AGE

6 Years, 8 Months


INTERPRETED BY

Nele Eley (Ondreka),
 DVM Dr. med. vet.,
 DipECVDI

The information and recommendations provided are based on the images presented by the referring veterinarian. No evaluation can be communicated regarding pathology that was not visible in the image/video clips provided.

HOSPITAL NAME

Mobile Pet Imaging

Thank you for this referral. If the clinical or image interpretation does not parallel your findings or if I can be of any further assistance please contact me.

REFERRING VET

Ciruta

Nele Eley (Ondreka), DVM, Dr. med. vet., DipECVDI
 European Specialist in Veterinary Diagnostic Imaging, Cert. Radiology,
 Senior lecturer University of Giessen/Germany, Veterinary Faculty, Department of Radiology.
info@sonopath.com

INVOICE

59352

DATE

7-13-23