



PATIENT PRESENTING CLINICAL SIGNS

Gordo Alvarez hemoptysis, loosing weight, lethargic. Multifocal Pulmonary Nodule

COMPUTED TOMOGRAPHIC STUDY OF THE THORAX & ABDOMEN

SPECIES
Canine Post contrast study of the thorax and plain and post contrast studies of the abdomen available for review.

COMPUTED TOMOGRAPHIC FINDINGS

BREED Abdomen

English Bulldog A 7 cm sized expansile cavitated mass is emerging from the quadrate liver lobe. Multiple small nodules and masses are seen throughout all liver lobes. The contrast enhancement of the mass and nodules is heterogeneous with predominance of peripheral enhancement.

SEX
MN The spleen presents within normal limits.

The kidneys, adrenal glands, pancreas, and gastrointestinal tract present within normal limits.

AGE Moderate canine hip dysplasia and mild osteoarthritis is seen.

7 Years, 10 Months There are multiple spondyloses and spondylarthroses throughout the lumbar spine.

Moderate degenerative lumbosacral stenosis is noted.

INTERPRETED BY
The patient's body condition score is slightly excessive.

Nele Eley (Ondreka),
DVM Dr. med. vet.,
DipECVDI

Thorax

Multiple variably sized soft tissue attenuating nodules of up to 4 cm size are seen throughout all lung lobes. Predominance of peripheral enhancement is seen within the nodules.

HOSPITAL NAME
The mediastinal lymph nodes present within normal limits.

Mobile Pet Imaging No evidence of pleural effusion is noted.

REFERRING VET No significant cardiovascular changes are seen.

Ciruta **COMPUTED TOMOGRAPHIC DIAGNOSIS**

- Large expansile central divisional liver mass and multiple hepatic nodules.
- Multiple pulmonary nodules.

INVOICE
59351 **INTERPRETATION OF FINDINGS & FURTHER RECOMMENDATIONS**

DATE
7-13-23 The CT findings are compatible with metastasizing neoplasia of the liver. Hemangiosarcoma is a primary differential diagnosis. Hepatocellular carcinoma and other neoplasia cannot be ruled out but is less likely. The additional nodules within the liver are highly likely to represent metastases.



PATIENT Metastases is a primary differential diagnosis for the pulmonary nodules as well.

Gordo Alvarez Metastasizing neoplasia should be considered a tentative diagnosis until proven otherwise. Granulomatous disease and multiple abscesses can never be ruled out entirely but are highly unlikely in this case unfortunately.

SPECIES Sampling of the pulmonary nodules and liver nodules/mass could be considered for a final diagnosis.

Canine

BREED

English Bulldog

SEX

MN

AGE

7 Years, 10 Months

INTERPRETED BY

Nele Eley (Ondreka),
DVM Dr. med. vet.,
DipECVDI

HOSPITAL NAME

Mobile Pet Imaging

REFERRING VET

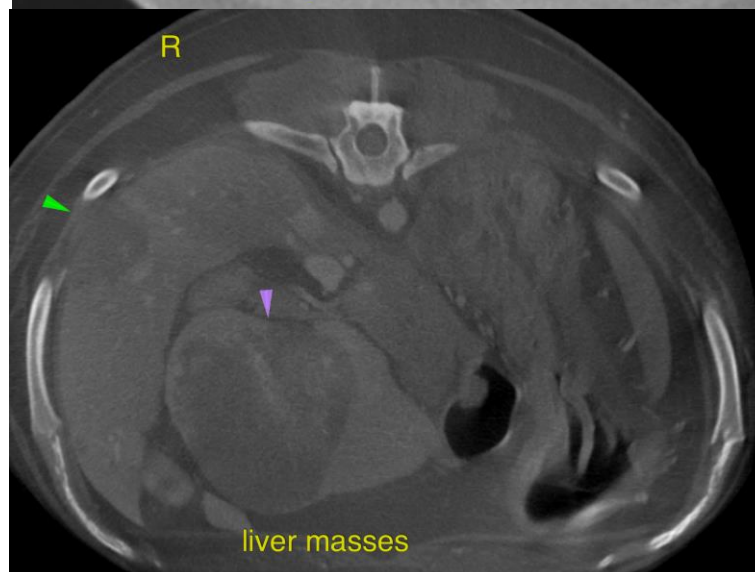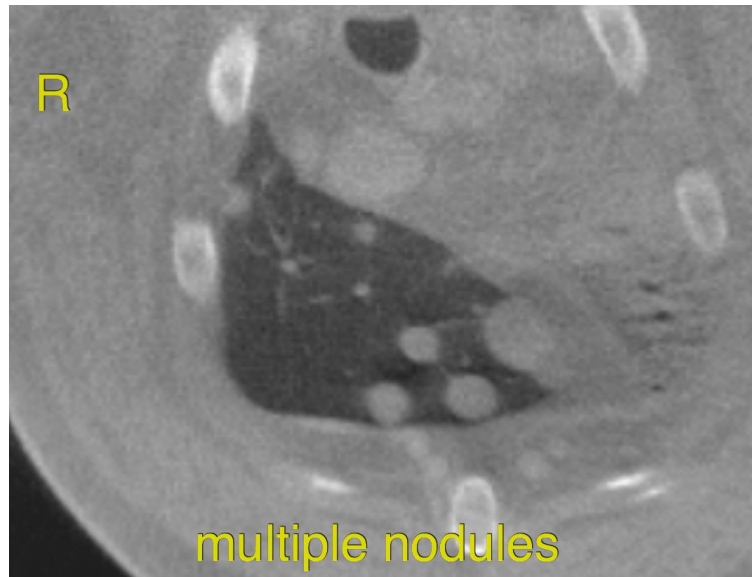
Ciruta

INVOICE

59351

DATE

7-13-23





PATIENT The information and recommendations provided are based on the images presented by the referring veterinarian. No evaluation can be communicated regarding pathology that was not visible in the image/video clips provided.

Gordo Alvarez

SPECIES

Thank you for this referral. If the clinical or image interpretation does not parallel your findings or if I can be of any further assistance please contact me.

Canine

Nele Eley (Ondreka), DVM, Dr. med. vet., DipECVDI
European Specialist in Veterinary Diagnostic Imaging, Cert. Radiology,
Senior lecturer University of Giessen/Germany, Veterinary Faculty, Department of Radiology.
info@sonopath.com

BREED

English Bulldog

SEX

MN

AGE

7 Years, 10 Months

INTERPRETED BY

Nele Eley (Ondreka),
DVM Dr. med. vet.,
DipECVDI

HOSPITAL NAME

Mobile Pet Imaging

REFERRING VET

Ciruta

INVOICE

59351

DATE

7-13-23