

**PATIENT**

Josie Bovine

SPECIES

Canine

BREED

Australian Kelpie Mix

SEX

FS

AGE

5 Years

INTERPRETED BYNele Eley, DVM
Dr. med. Vet. DipECVDI**HOSPITAL NAME**Southern Oregon
Veterinary Specialty
Center**REFERRING VET**

Dr. Fugazzi

INVOICE

52855

DATE

7-13-22

PRESENTING CLINICAL SIGNS

Presenting Complaint: Josie presented with inability to use forelimbs When did you first notice the problem? Started about a month ago with weakness and has progressed Has Josie had any previous history of this? None Does the patient have any underlying conditions?? None reported Has Josie had any diagnostics or procedures Rads at rdvm How has Josie's appetite been? Good When did Josie last eat? - Have you noticed any vomiting, diarrhea, urinary concerns, coughing, or any other abnormal signs? None reported If so, when did you first notice these? - Are you currently giving Josie any medications or supplements? Was on Rimadyl and Tramadol but Tramadol made her too sedate. They switched her to a stronger steroid but owner cannot remember what its called.

COMPUTED TOMOGRAPHIC STUDY OF THE CERVICAL SPINE

Plain study and myelogram of the cervical spine available for review.

COMPUTED TOMOGRAPHIC FINDINGS

Number, alignment, and general anatomy of the cervical vertebrae present within normal limits. The intervertebral discs are in situ. No deviation, compression, or abnormal widening of the subarachnoid space are seen. No change in attenuation of the spinal cord can be identified. There is no evidence of traumatic osseous injury, discospondylitis, or aggressive bone lesions.

COMPUTED TOMOGRAPHIC DIAGNOSIS

- Normal CT findings of the cervical spine on plain study and myelogram.

INTERPRETATION OF THE FINDINGS & FURTHER RECOMMENDATIONS

The negative CT myelogram rules out presence of compressive myelopathy. Differential diagnosis includes neuromuscular disease including polyradiculoneuropathy and other. Non-compressive diseases including meningitis, myelitis, vascular pathology such as ischemic, and hemorrhagic, as well as neurodegenerative disease cannot be ruled out. Complementary csf analysis could be considered for further definition.



PATIENT

Josie Bovine

SPECIES

Canine

BREED

Australian Kelpie Mix

SEX

FS

AGE

5 Years

INTERPRETED BY

Nele Eley, DVM
Dr. med. Vet. DipECVDI

HOSPITAL NAME

Southern Oregon
Veterinary Specialty
Center

REFERRING VET

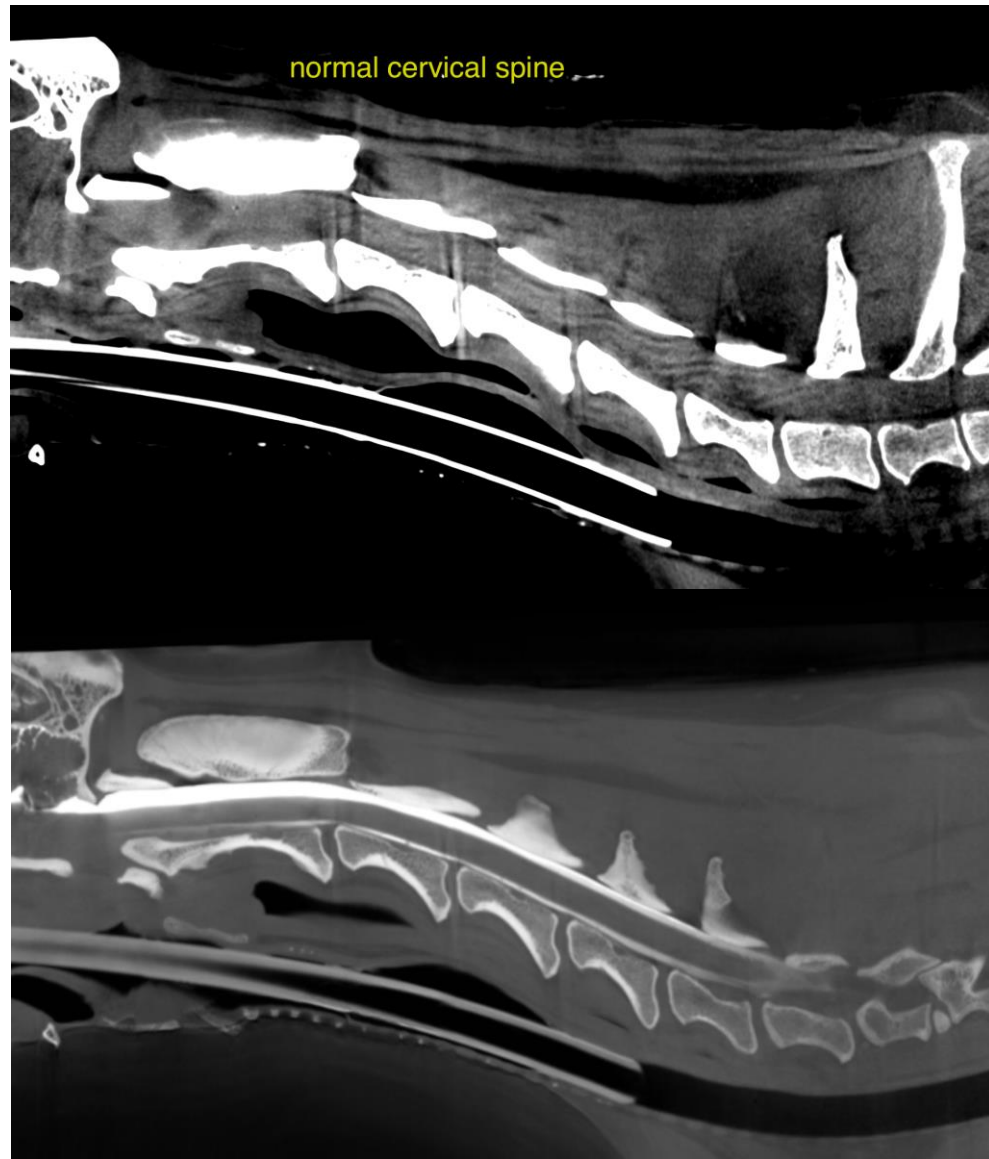
Dr. Fugazzi

INVOICE

52855

DATE

7-13-22





PATIENT

Josie Bovine

The information and recommendations provided are based on the images presented by the referring veterinarian/sonographer. No evaluation can be communicated regarding pathology that was not visible in the image/video clips provided.

Thank you for this referral. If the clinical or image interpretation does not parallel your findings or if I can be of any further assistance please contact me.

SPECIES

Canine

Nele Eley, DVM, Dr. med. vet., DipECVDI
European Specialist in Veterinary Diagnostic Imaging, Cert. Radiology,
Senior lecturer University of Giessen, Germany, Veterinary Faculty, Department of Radiology
Nele.Eley@sonopath.com

BREED

Australian Kelpie Mix

SEX

FS

AGE

5 Years

INTERPRETED BY

Nele Eley, DVM
Dr. med. Vet. DipECVDI

HOSPITAL NAME

Southern Oregon
Veterinary Specialty
Center

REFERRING VET

Dr. Fugazzi

INVOICE

52855

DATE

7-13-22