



PATIENT

Cassie Dougherty

SPECIES

Feline

BREED

DSH

SEX

SF

AGE

10 Years

INTERPRETED BY

Nele Eley, DVM
Dr. med. Vet. DipECVDI

HOSPITAL NAME

Brunswick Veterinary
Hospital

REFERRING VET

Dr. Heather Burrows

INVOICE

52854

DATE

7-13-22

PRESENTING CLINICAL SIGNS

Presented for approx 2-3 week history of slowly progressive dyspnea and tachypnea. BARH on presentation, no murmurs or arrhythmias, but heart sounds were louder ventrally. Several months ago, there was also a history of either syncopal or seizure episodes, but they have not reoccurred. Unable to obtain VD view or better positioned DV view as patient experienced respiratory distress.

RADIOGRAPHIC STUDY OF THE THORAX

Right lateral and dorsoventral views totaling 2 images available for review.

RADIOGRAPHIC FINDINGS

The chest is expanded. The lungs are deeply inflated.

A cranioventrally accentuated increase in pulmonary opacity is seen. A generalized interstitial lung pattern is noted.

The cardiac silhouette is obscured by the pulmonary infiltrate but appears to be enlarged. The orthogonal view does not allow for a more detailed assessment owing to the positioning. However, presence of a minimal amount of pleural effusion is suggested.

There is moderate gastric aerophagia likely due to respiratory distress.

RADIOGRAPHIC DIAGNOSIS

- Suspect cardiomegaly
- Ventrally accentuated interstitial lung pattern.
- Minimal pleural effusion.

INTERPRETATION OF THE FINDINGS & FURTHER RECOMMENDATIONS

Differential diagnosis includes pericardial effusion, cardiomegaly due to cardiomyopathy, and less likely PPDH.

Pulmonary changes may represent edema and less likely pneumonia/pneumonitis.

Further definition by means of a full cardiac echo or fast thoracic ultrasound depending on patient compliance and stress is recommended.



PATIENT

Cassie Dougherty

SPECIES

Feline

BREED

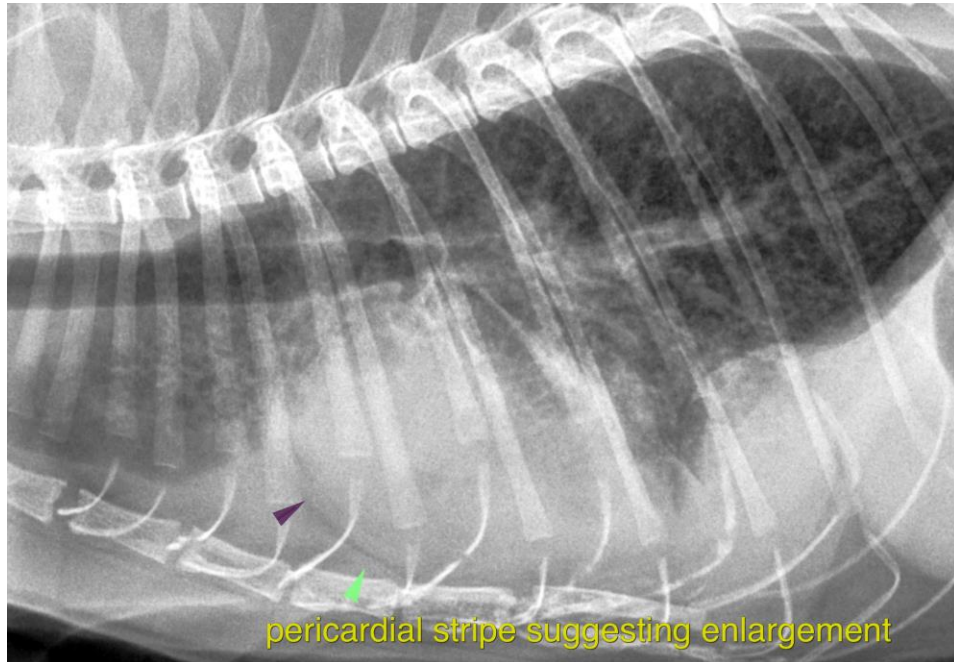
DSH

SEX

SF

AGE

10 Years



INTERPRETED BY

Nele Eley, DVM
Dr. med. Vet. DipECVDI

The information and recommendations provided are based on the images presented by the referring veterinarian/sonographer. No evaluation can be communicated regarding pathology that was not visible in the image/video clips provided.

Thank you for this referral. If the clinical or image interpretation does not parallel your findings or if I can be of any further assistance please contact me.

HOSPITAL NAME

Brunswick Veterinary
Hospital

Nele Eley, DVM, Dr. med. vet., DipECVDI
European Specialist in Veterinary Diagnostic Imaging, Cert. Radiology,
Senior lecturer University of Giessen, Germany, Veterinary Faculty, Department of Radiology
Nele.Eley@sonopath.com

REFERRING VET

Dr. Heather Burrows

INVOICE

52854

DATE

7-13-22