



**PATIENT**

Sophie Szafran

**PRESENTING CLINICAL SIGNS**

Has had some coughing past 5 months reported as dry hack to slightly like a goose honk. Was progressing slowly but was exacerbated while camping 1 week prior in warmer weather. Yesterday little coughing and none today. Son of this dog was diagnosed with collapsing trachea. Abnormal PE/Chem/CBC/UA Results: SI raspy lung fields ausculted bilaterally

**SPECIES**

Canine

**RADIOGRAPHIC STUDY OF THE THORAX**

Right/left lateral and ventrodorsal views of the thorax totaling 3 images available for review.

**BREED**

Chihuahua Mix

**RADIOGRAPHIC FINDINGS**

Abundance of subcutaneous mediastinal and pericardial fat are seen.

**SEX**

Female Spayed

The vertebral heart score is 10.5. No specific chamber enlargement is seen and there is no evidence of cardiogenic pulmonary edema.

The degree of pulmonary inflation is fair. A mild generalized bronchial lung pattern is noted.

**AGE**

15 Years

Severe collapse of the cervical trachea from caudal to the larynx up to the thoracic inlet is seen on both lateral views.

There is mild generalized enlargement of the liver and mild gastric aerophagia.

**INTERPRETED BY**

Nele Eley, DVM  
Dr. med. Vet. DipECVDI

**RADIOGRAPHIC DIAGNOSIS**

- Severe cervical tracheal collapse.
- Mild bronchial lung pattern.
- Hepatomegaly.
- Obesity.

**HOSPITAL NAME**

Blandford Animal Hospital

**INTERPRETATION OF THE FINDINGS & FURTHER RECOMMENDATIONS**

The radiographic study reveals severe cervical tracheal collapse which is likely the cause of the patient's clinical signs based on its severity.

**REFERRING VET**

Lapierre

The mild bronchial lung pattern may well be within age related normal limits, however, low grade chronic lower airway disease such as eosinophilic bronchopneumopathy and less likely infectious bronchitis cannot be ruled out entirely. Further workup by means of upper and lower airway endoscopy with airway sampling could be considered.

**INVOICE**

52841

Differential diagnosis for the hepatomegaly includes metabolic/endocrine hepatopathy as well as diffuse inflammatory/infectious and less likely diffuse neoplastic infiltrates. Correlate with the laboratory values and consider further workup by means of ultrasound with eventual sampling if indicated.

**DATE**

7-12-22



**PATIENT**

Sophie Szafran

**SPECIES**

Canine

**BREED**

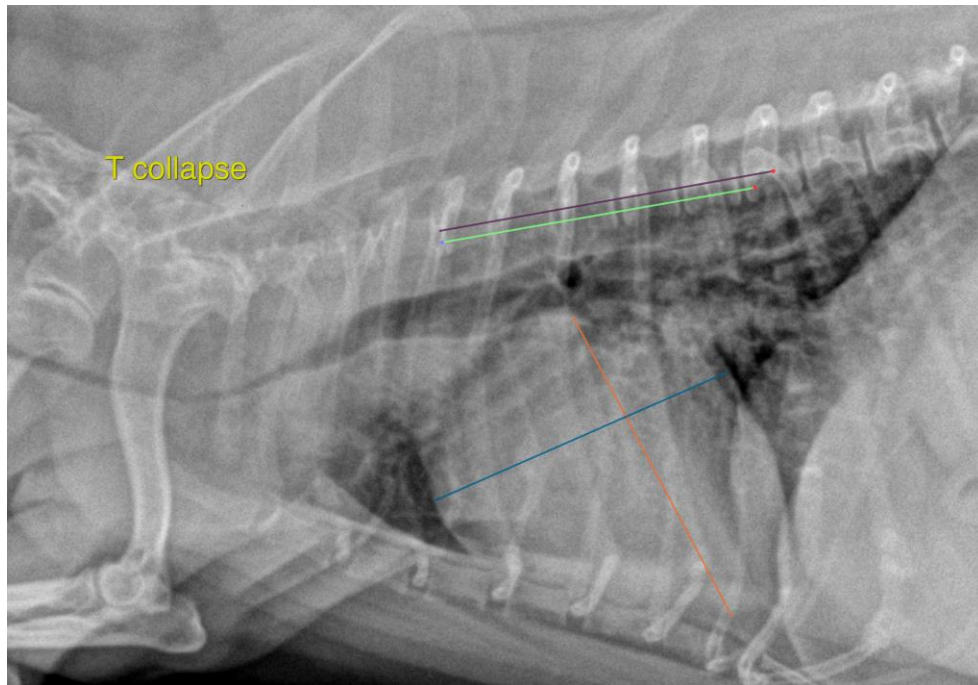
Chihuahua Mix

**SEX**

Female Spayed

**AGE**

15 Years



**INTERPRETED BY**

Nele Eley, DVM  
Dr. med. Vet. DipECVDI

The information and recommendations provided are based on the images presented by the referring veterinarian/sonographer. No evaluation can be communicated regarding pathology that was not visible in the image/video clips provided.

Thank you for this referral. If the clinical or image interpretation does not parallel your findings or if I can be of any further assistance please contact me.

**HOSPITAL NAME**

Blandford Animal  
Hospital

**Nele Eley**, DVM, Dr. med. vet., DipECVDI  
European Specialist in Veterinary Diagnostic Imaging, Cert. Radiology,  
Senior lecturer University of Giessen, Germany, Veterinary Faculty, Department of Radiology  
Nele.Eley@sonopath.com

**REFERRING VET**

Lapierre

**INVOICE**

52841

**DATE**

7-12-22