



PATIENT PRESENTING CLINICAL SIGNS

Zeus Neenan P has been having chronic ear problems for the past couple of months. Dr. suspected masses were observed in the ears on the last physical exam. Performed CT to confirm if masses are present.

SPECIES COMPUTED TOMOGRAPHIC STUDY OF THE HEAD

Canine Plain and post contrast studies available for review.

COMPUTED TOMOGRAPHIC FINDINGS

BREED
DSH
The brain presents no deviation from normal anatomy and symmetry. The grey and white matter distinction and the neuroparenchymal attenuation are as expected. The distribution of contrast enhancement is within normal limits throughout the parenchyma and meninges. The ventricular system is non-dilated and within the limits of the expected volume and symmetry.

SEX
MN
Thin and smoothly folded conchae and turbinates with even smooth mucosal lining. The osseous lining of the nasal cavities is intact.

Both temporomandibular joints present congruent joint spaces with even subchondral bone surfaces and are considered within normal limits.

AGE
8 Years
Thickening of the epithelial lining of the bilateral external auditory meatuses is seen. There are elongated soft tissue attenuating structures in the horizontal medial part of the external auditory meatuses. The right measures 16 x 3.5mm and expands the external auditory meatus slightly. The left measures 13 x 3mm. The contrast enhancement pattern of these structures is mild and uniform. Mild mucosal swelling and mild thickening of the osseous lining of the right tympanic bulla are seen.

INTERPRETED BY

Nele Eley, DVM
Dr. med. Vet. DipECVDI

The bilateral medial retropharyngeal lymph nodes present mild symmetric enlargement.

HOSPITAL NAME

Catskill Veterinary
Services, PLLC

The salivary glands present within normal limits.

The visible dentition is within normal limits.

COMPUTED TOMOGRAPHIC DIAGNOSIS

REFERRING VET

Dr. Janis McGill

- Chronic bilateral otitis externa with ear canal polyp formation.
- Mild chronic right hand sided otitis media.
- Mild bilateral medial retropharyngeal lymphadenomegaly compatible with reactive lymphadenitis.

INVOICE

59301

INTERPRETATION OF THE FINDINGS & FURTHER RECOMMENDATIONS

The CT findings suggest presence of ear canal polyps within both external auditory meatuses. There are signs of chronic otitis externa bilaterally. The right middle ear presents signs of mild concurrent chronic otitis media.

DATE

7-11-23

The lymph node changes are compatible with reactive lymphadenitis.

There is no evidence of nasopharyngeal polyp formation and no evidence of otitis media on the



PATIENT

left hand side.

Zeus Neenan

SPECIES

Canine

BREED

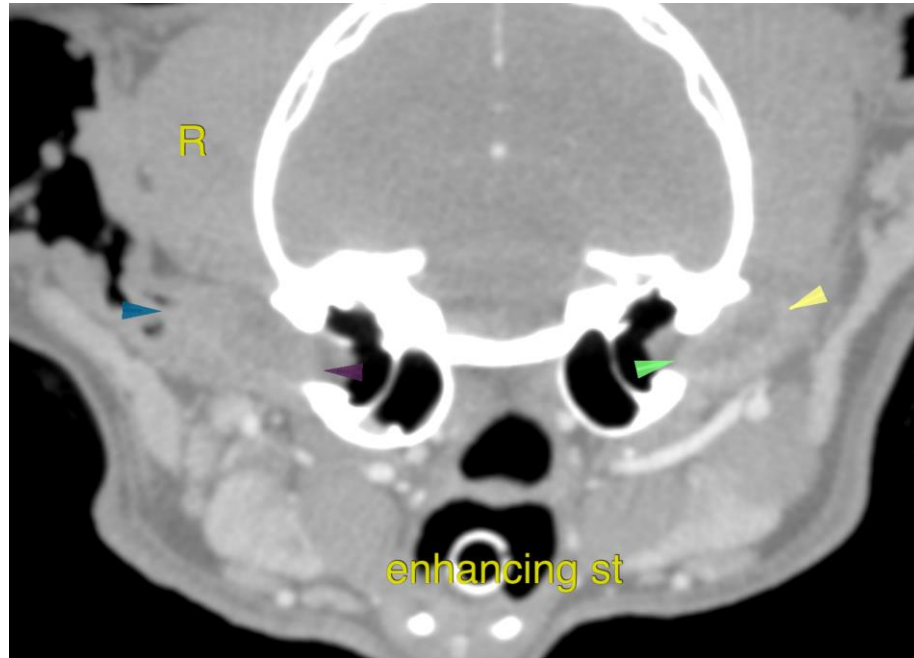
DSH

SEX

MN

AGE

8 Years



INTERPRETED BY

Nele Eley, DVM
Dr. med. Vet. DipECVDI

The information and recommendations provided are based on the images presented by the referring veterinarian/sonographer. No evaluation can be communicated regarding pathology that was not visible in the image/video clips provided.

HOSPITAL NAME

Catskill Veterinary
Services, PLLC

Thank you for this referral. If the clinical or image interpretation does not parallel your findings or if I can be of any further assistance please contact me.

Nele Eley, DVM, Dr. med. vet., DipECVDI
European Specialist in Veterinary Diagnostic Imaging, Cert. Radiology,
Senior lecturer University of Giessen, Germany, Veterinary Faculty, Department of Radiology
info@sonopath.com

REFERRING VET

Dr. Janis McGill

INVOICE

59301

DATE

7-11-23