



**PATIENT**

Frisco Gray

**SPECIES**

Equine

**BREED**

Miniature Horse

**SEX**

Gelding

**AGE**

17 Years

**INTERPRETED BY**

Nele Eley, DVM  
Dr. med. Vet. DipECVDI

**HOSPITAL NAME**

Rivers Edge Pet  
Medical Center

**REFERRING VET**

Leah Gray DVM,  
DACVIM, CVA

**INVOICE**

59313

**DATE**

7-11-23

**PRESENTING CLINICAL SIGNS**

3 day history of acute trauma to the left shoulder region from another horse. Severe swelling over triceps and pain especially over point of shoulder. Goal for patient is to return to driving  
Abnormal PE/Chem/CBC/UA Results: Radiographs showed possible step lesion on glenoid process (see attached)

**ULTRASONOGRAPHIC FINDINGS**

The patient has a history of traumatic injury 3 days prior to the ultrasonographic examination.

**Left & Right Shoulder Region**

Distortion, heterogeneity, and severe swelling of the left biceps tendon are seen. There is severe anechoic effusion level with the bicipital tendon sheath and joint space in the left shoulder.

The triceps of the left thoracic limb presents generalized swelling with overall heterogeneity with multiple hypoechoic areas and partial loss of the muscular echoarchitecture.

The right shoulder region was scanned for comparison and no structural abnormalities were identified.

**ULTRASONOGRAPHIC DIAGNOSIS**

- Suspect biceps tendon and triceps injury of the left shoulder.

**INTERPRETATION OF THE FINDINGS & FURTHER RECOMMENDATIONS**

Limited study.

The ultrasonographic findings suggest acute injury of the left biceps tendon with tendon sheath and joint effusion. The severe swelling and distortion may stem from direct injury or partial rupture of the tendon. Concurrent presence of osseous injury and glenoid labrum injury cannot be ruled out and cross referencing the ultrasonographic findings with the radiographs is recommended.

The changes of the triceps are more suggestive for traumatic myositis and hematoma formation rather than muscular rupture.



**PATIENT**

Frisco Gray

**SPECIES**

Equine

**BREED**

Miniature Horse

**SEX**

Gelding

**AGE**

17 Years

**INTERPRETED BY**

Nele Eley, DVM  
Dr. med. Vet. DipECVDI

**HOSPITAL NAME**

Rivers Edge Pet  
Medical Center

**REFERRING VET**

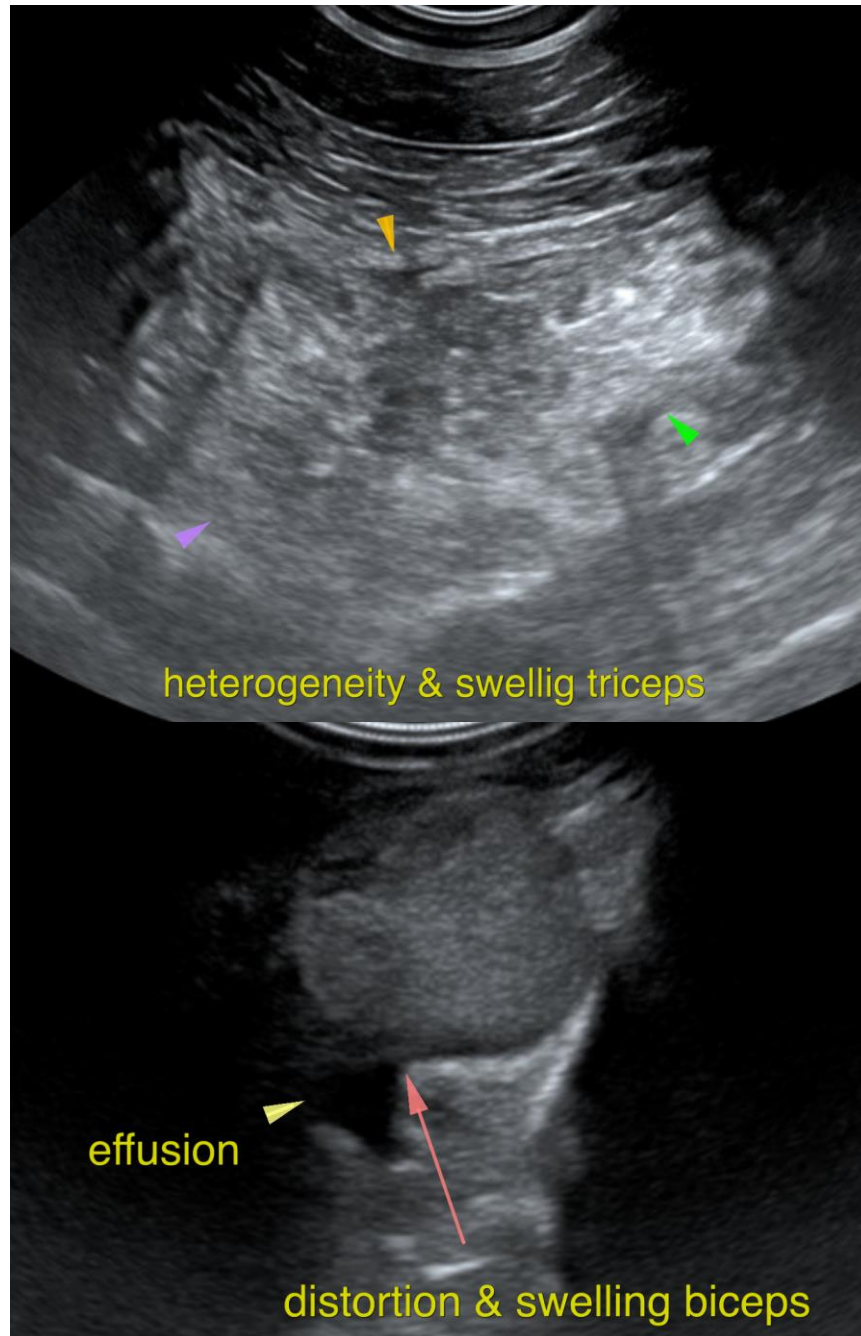
Leah Gray DVM,  
DACVIM, CVA

**INVOICE**

59313

**DATE**

7-11-23





**PATIENT**

Frisco Gray

The information and recommendations provided are based on the images presented by the referring veterinarian/sonographer. No evaluation can be communicated regarding pathology that was not visible in the image/video clips provided.

Thank you for this referral. If the clinical or image interpretation does not parallel your findings or if I can be of any further assistance please contact me.

**SPECIES**

Equine

**Nele Eley**, DVM, Dr. med. vet., DipECVDI  
European Specialist in Veterinary Diagnostic Imaging, Cert. Radiology,  
Senior lecturer University of Giessen, Germany, Veterinary Faculty, Department of Radiology  
[info@sonopath.com](mailto:info@sonopath.com)

**BREED**

Miniature Horse

**SEX**

Gelding

**AGE**

17 Years

**INTERPRETED BY**

Nele Eley, DVM  
Dr. med. Vet. DipECVDI

**HOSPITAL NAME**

Rivers Edge Pet  
Medical Center

**REFERRING VET**

Leah Gray DVM,  
DACVIM, CVA

**INVOICE**

59313

**DATE**

7-11-23