



PATIENT PRESENTING CLINICAL SIGNS

Brooke Muirhead June 20,23 collapsed after going out in the yard. Dragging hind legs and unable to walk. On exam heavy panting, stridor, hind end paresis, bilaterally but ambulatory for several steps on her own, and then slips. Bloodwork performed showing moderate neutrophilia, mild monocytosis rest of values within normal limits. Chemistry showed elevated liver enzyme (ALP). On June 23,23 thoracic radiographs showed a pulmonary mass. Rule out primary lung tumor (carcinoma, histiocytic sarcoma, others), metastatic lung tumor, Fungal infection or abscess. Abnormal PE/Chem/CBC/UA Results: n/a

SPECIES

Canine

BREED

Labrador

COMPUTED TOMOGRAPHIC STUDY OF THE THORAX & ABDOMEN

Plain and post contrast studies available for review in soft tissue, bone, and lung windows.

COMPUTED TOMOGRAPHIC FINDINGS

SEX

FS

Thorax

Moderate bilateral shoulder osteoarthritis with bicipital groove exostoses are seen.

AGE

13 Years

There are mild to moderate spondyloses within the thoracic spine.

A 6 x 4.5cm sized irregular shaped soft tissue attenuating mass with multifocal mineralizations is seen in the right caudal lung lobe. Multifocal compression of second and third order bronchi is seen. The mass presents diffuse heterogeneous enhancement with multiple small cavitations sparing contrast media. No signs of peripheral inflammation are seen.

INTERPRETED BY

Nele Eley, DVM
Dr. med. Vet. DipECVDI

The mediastinal lymph nodes and remainder of the lung present within age related normal limits.

Abdomen

Severe degenerative lumbosacral stenosis is seen.

HOSPITAL NAME

Animal Health
Partners

The bilateral coxofemoral joints present a vacuum phenomenon and moderate signs of dysplasia and osteoarthritis are present as well.

REFERRING VET

Jerome Gagnon

The left kidney is small with disarranged architecture and weak and heterogeneous nephrogram measuring only 2 cm in diameter and 4 cm in length. The right kidney presents occasional cortical renal cysts and infarcts but is otherwise within normal limits.

Multinodular enlargement of the left adrenal gland with cranial and caudal pole diameters of 1.5 cm is seen.

INVOICE

59298

The liver and spleen present within expected limits.

The abdominal lymph nodes and gastrointestinal tract present within normal limits.

DATE

7-11-23

Mineral attenuating foci and polypoid mucosal hyperplasia are seen within the gallbladder.



PATIENT

Brooke Muirhead

SPECIES

Canine

BREED

Labrador

SEX

FS

AGE

13 Years

INTERPRETED BY

Nele Eley, DVM
Dr. med. Vet. DipECVDI

HOSPITAL NAME

Animal Health
Partners

REFERRING VET

Jerome Gagnon

INVOICE

59298

DATE

7-11-23

COMPUTED TOMOGRAPHIC DIAGNOSIS

- Large pulmonary mass within the right caudal lung lobe meeting neoplastic criteria.
- Multinodular presentation of the left adrenal gland.
- Suspect end stage renal disease of the left kidney.
- Gallbladder microlithiasis and polypoid mucosal hyperplasia.
- Severe degenerative lumbosacral stenosis.
- Bilateral coxofemoral joint and shoulder joint osteoarthritis.
- Spondyloses.

INTERPRETATION OF THE FINDINGS & FURTHER RECOMMENDATIONS

The CT study reveals a perfused and mineralizing soft tissue mass within the right caudal lung lobe. Primary neoplasia of the lung is considered by far most likely. Secondary neoplasia of the lung, abscess, granuloma can never be ruled out entirely but are thought by far less likely here. The mass is accessible for ultrasound guided sampling if this is an option. The main challenge is the thickness of the thoracic wall due to presence of subcutaneous fat so that long needles may be require and sedation should be applied.

The findings of the kidneys suggest potential for bilateral nephritis with end stage renal disease of the left kidney. Congenital dysplasia or other cannot be ruled out entirely but are thought by far less likely. Correlation with the laboratory values recommended.

The multinodular appearance of the left adrenal gland can be due to incidentalomas, myelolipoma, functional or nonfunctional hyperplasia, or small adenomas. Adenocarcinoma, pheochromocytoma, and metastatic disease are considered less likely but cannot be ruled out entirely.



PATIENT

Brooke Muirhead

SPECIES

Canine

BREED

Labrador

SEX

FS

AGE

13 Years

INTERPRETED BY

Nele Eley, DVM
Dr. med. Vet. DipECVDI

HOSPITAL NAME

Animal Health
Partners

REFERRING VET

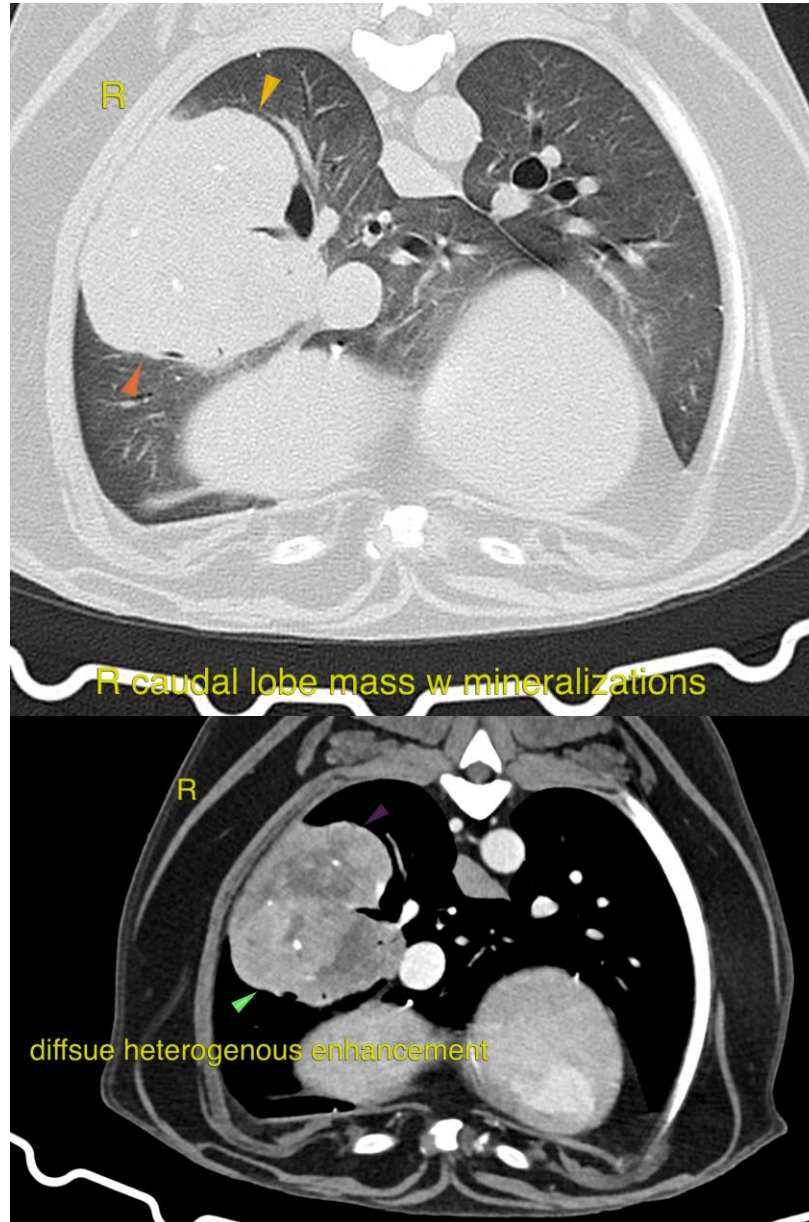Jerome Gagnon

INVOICE

59298

DATE

7-11-23





PATIENT

Brooke Muirhead

SPECIES

Canine

BREED

Labrador

SEX

FS

AGE

13 Years

INTERPRETED BY

Nele Eley, DVM
Dr. med. Vet. DipECVDI

HOSPITAL NAME

Animal Health
Partners

REFERRING VET

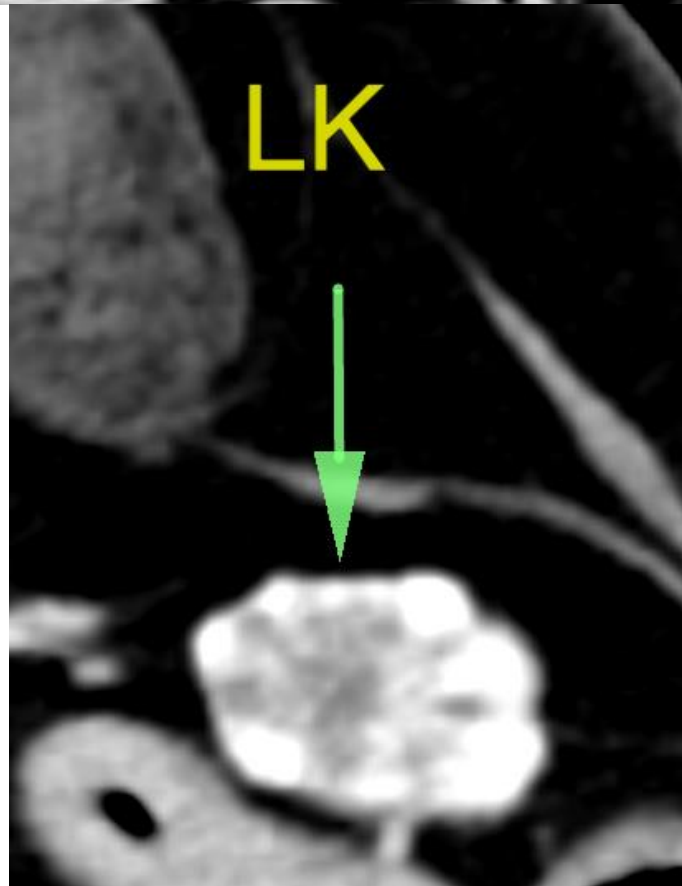
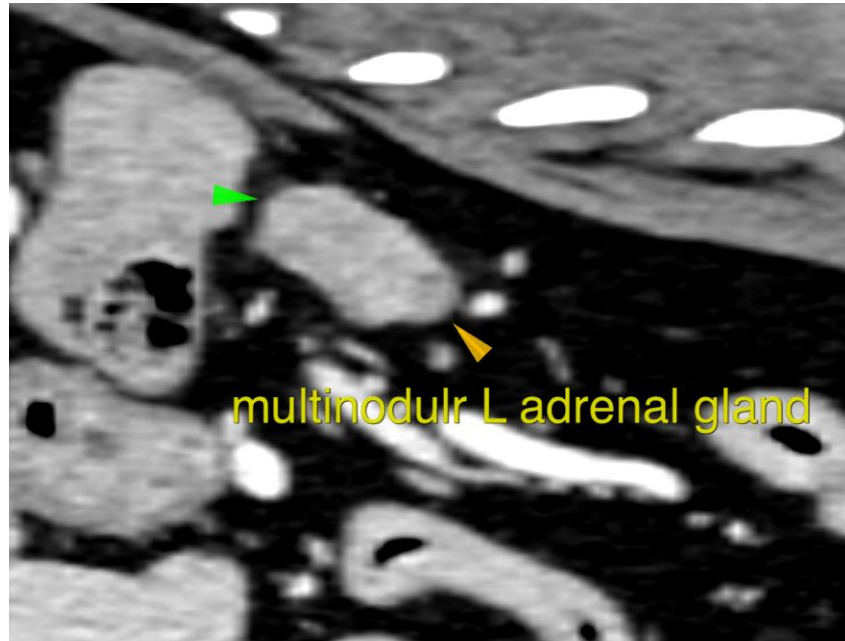
Jerome Gagnon

INVOICE

59298

DATE

7-11-23





PATIENT

Brooke Muirhead

The information and recommendations provided are based on the images presented by the referring veterinarian/sonographer. No evaluation can be communicated regarding pathology that was not visible in the image/video clips provided.

SPECIES

Canine

Thank you for this referral. If the clinical or image interpretation does not parallel your findings or if I can be of any further assistance please contact me.

BREED

Labrador

Nele Eley, DVM, Dr. med. vet., DipECVDI
European Specialist in Veterinary Diagnostic Imaging, Cert. Radiology,
Senior lecturer University of Giessen, Germany, Veterinary Faculty, Department of Radiology
info@sonopath.com

SEX

FS

AGE

13 Years

INTERPRETED BY

Nele Eley, DVM
Dr. med. Vet. DipECVDI

HOSPITAL NAME

Animal Health
Partners

REFERRING VET

Jerome Gagnon

INVOICE

59298

DATE

7-11-23