

**PATIENT**

Zeke Valanj

PRESENTING CLINICAL SIGNS

History of bilateral cranial cruciate disease with bilateral tplo repair done 3 years ago.. Hasn't ever returned to normal. Still walks gingerly and cannot go on long walks. still presents for left hind lameness. The left stifle has crepitus but no meniscal click. no pain upon palpation of implants. great hip extension. does not exhibit pain with spinal palpation. there is repeatable iliopsoas discomfort and pain in left.

SPECIES

Canine

ULTRASONOGRAPHIC FINDINGS OF THE PSOAS MAJOR TENDONS IN BOTH HIND LIMBS**BREED**

Lab Mix

Subjectively, mild swelling, irregular outline, and echoarchitectural remodeling of the psoas major tendon is seen level with the musculotendinous junction and the tendon's attachment to the lesser trochanter of the femur in both hind limbs. The changes appear to be slightly more pronounced on the left when compared with the right side.

SEX

MN

Both coxofemoral joints present mild generalized thickening of their synovium and scant anechoic effusion as well as osseous remodeling of the femoral head.

AGE

5 Years

- Suspect chronic bilateral psoas major tendinopathy.
- Suspect age related remodeling of both coxofemoral joints.

INTERPRETATION OF THE FINDINGS & FURTHER RECOMMENDATIONS

The ultrasonographic changes are mild yet suggest presence of chronic bilateral psoas major injury. Chronic repetitive microtrauma with tendinitis is a potential versus age related remodeling of the tendon fibers. Clinical correlation is required.

The changes of the coxofemoral joints are very subtle and likely to be within the age related normal limits.

INTERPRETED BY

Nele Eley, DVM
Dr. med. Vet. DipECVDI

HOSPITAL NAME

SVS Imaging

REFERRING VET

Dr. Thompson

INVOICE

52801

DATE

7-11-22



PATIENT

Zeke Valanj

SPECIES

Canine

BREED

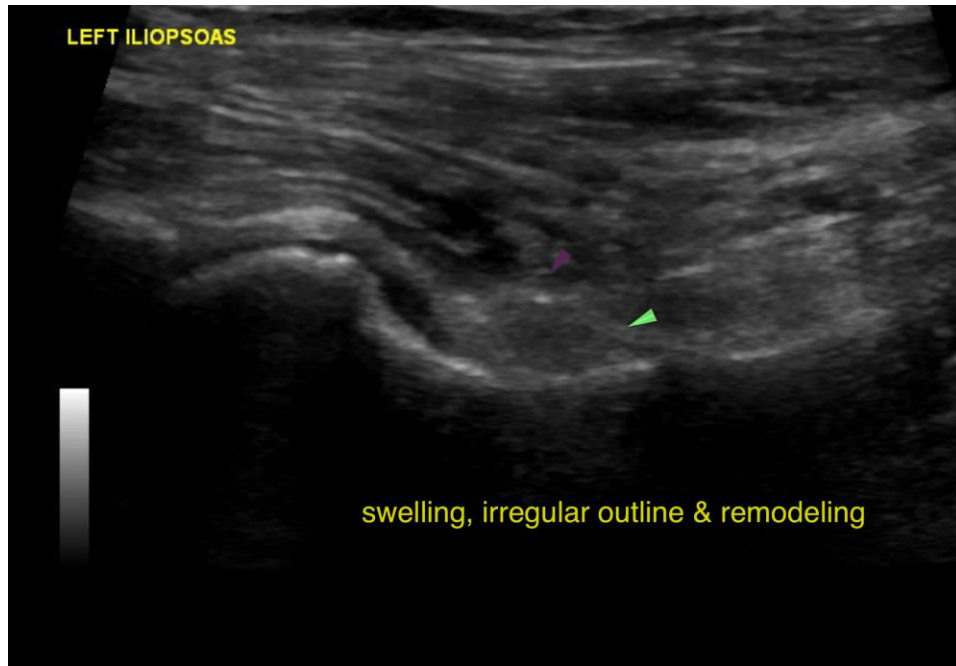
Lab Mix

SEX

MN

AGE

5 Years



INTERPRETED BY

Nele Eley, DVM
Dr. med. Vet. DipECVDI

The information and recommendations provided are based on the images presented by the referring veterinarian/sonographer. No evaluation can be communicated regarding pathology that was not visible in the image/video clips provided.

Thank you for this referral. If the clinical or image interpretation does not parallel your findings or if I can be of any further assistance please contact me.

HOSPITAL NAME

SVS Imaging

Nele Eley, DVM, Dr. med. vet., DipECVDI
European Specialist in Veterinary Diagnostic Imaging, Cert. Radiology,
Senior lecturer University of Giessen, Germany, Veterinary Faculty, Department of Radiology
Nele.Eley@sonopath.com

REFERRING VET

Dr. Thompson

INVOICE

52801

DATE

7-11-22