



**PATIENT**

Vern Wild

**PRESENTING CLINICAL SIGNS**

Heart murmur-moderate sounding. Rule out CHF. 2nd seizure in 2 months.

**SPECIES**

Canine

**RADIOGRAPHIC STUDY OF THE THORAX**

Right lateral and ventrodorsal views totaling 2 images available for review.

**BREED**

Chihuahua

**RADIOGRAPHIC FINDINGS**

The degree of pulmonary inflation is moderate. The bronchopulmonary structures present within normal limits.

Course and width of the trachea are considered within normal limits.

**SEX**

M

The cardiac silhouette presents no significant enlargement. The vertebral heart score is 9.6 with reference range up to 10.5. No specific chamber enlargement is noted. The pulmonary vasculature presents within normal limits. There is no evidence of pulmonary venous congestion or cardiogenic pulmonary edema.

**AGE**

6 Years, 11 Months

No significant cranial mediastinal widening is seen.

The liver margins are slightly beyond the costal arch yet pointed.

Mild gastric aerophagia is noted.

**INTERPRETED BY**

Nele Eley, DVM  
Dr. med. Vet. DipECVDI

**RADIOGRAPHIC DIAGNOSIS**

- Normal radiographic presentation of the thorax.

**HOSPITAL NAME**

River Valley  
Veterinary Wellness  
Clinic

**INTERPRETATION OF THE FINDINGS & FURTHER RECOMMENDATIONS**

The radiographic study did not reveal significant bronchopulmonary or cardiovascular changes. There is no radiographic evidence of cardiac volume overload or cardiogenic pulmonary edema/congestive cardiac failure. Valvular insufficiencies most commonly secondary to endocardiosis remain a potential and are considered likely based on the patient history. However, at this time there is no evidence of decompensation. A full cardiac echo could be considered for a more detailed assessment of the cardiac morphology and function.

**REFERRING VET**

Dr. Devashree Pala

**INVOICE**

59295

**DATE**

7-10-23



**PATIENT**

Vern Wild

**SPECIES**

Canine

**BREED**

Chihuahua

**SEX**

M

**AGE**

6 Years, 11 Months

**INTERPRETED BY**

Nele Eley, DVM  
Dr. med. Vet. DipECVDI

**HOSPITAL NAME**

River Valley  
Veterinary Wellness  
Clinic

**REFERRING VET**

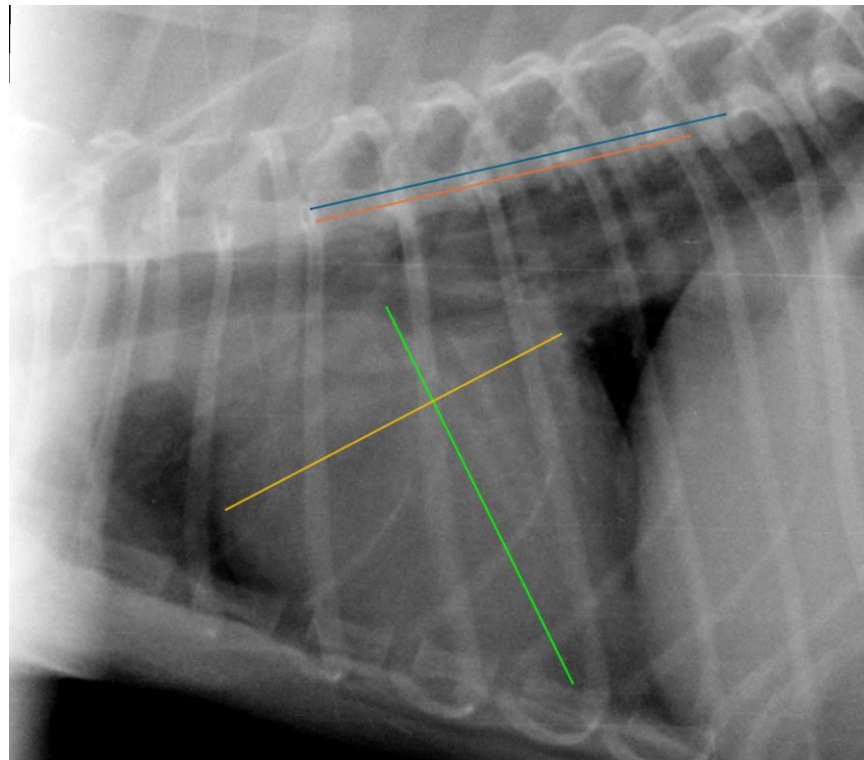
Dr. Devashree Pala

**INVOICE**

59295

**DATE**

7-10-23



The information and recommendations provided are based on the images presented by the referring veterinarian/sonographer. No evaluation can be communicated regarding pathology that was not visible in the image/video clips provided.

Thank you for this referral. If the clinical or image interpretation does not parallel your findings or if I can be of any further assistance please contact me.

**Nele Eley**, DVM, Dr. med. vet., DipECVDI  
European Specialist in Veterinary Diagnostic Imaging, Cert. Radiology,  
Senior lecturer University of Giessen, Germany, Veterinary Faculty, Department of Radiology  
[info@sonopath.com](mailto:info@sonopath.com)