

**PATIENT**

Yogie Buchanan

PRESENTING CLINICAL SIGNS

P presents for limping - O took P on walk yesterday, came home and P was barely able to move, falling over. Gave baby aspirin. P seems to be doing better this morning, but not completely back to normal. Favoring LHL. While P was sedated, able to feel drawer sign.

SPECIES

Canine

RADIOGRAPHIC STUDY OF THE PELVIS & STIFLES

Ventrodorsal hip extended view of the pelvis and mediolateral and craniocaudal views of both stifles totaling 6 images available for review.

BREED

Spaniel Mix

RADIOGRAPHIC FINDINGS**Pelvis**

The coxofemoral joint spaces are congruent but slightly widened. Femoral head coverage appears to be adequate. No significant osteoarthritic changes are seen and there is no evidence of cranial or lateral subluxation.

SEX

Male Neutered

The muscle volume of the right hind limb appears to be reduced when compared with the left side.

AGE

10 Years

Stifles

Severe articular swelling of the right stifle joint is seen. There is moderate osteophytosis at the proximal contour of the femoral trochlea. Mild cranial thrust of the tibia is seen.

INTERPRETED BYNele Eley, DVM
Dr. med. Vet. DipECVDI

The left stifle joint presents mild articular swelling. No obvious cranial thrust of the tibia is noted. There is no evidence of periarticular osteophytes.

HOSPITAL NAMEThe Pet Hospital of
Stratford

The patellae are in situ in both stifles.

RADIOGRAPHIC DIAGNOSIS

- Severe articular enlargement, mild osteoarthritis, and cranial thrust of the tibia of the right hind limb.
- Disuse atrophy of the right hind limb musculature.

REFERRING VETDr. Claudia Giuliani,
DVM**INTERPRETATION OF THE FINDINGS & FURTHER RECOMMENDATIONS**

The radiographic findings support the presence of cranial cruciate ligament injury with concurrent osteoarthritis in the right stifle. The muscle atrophy of the right hind limb is likely secondary to chronic disuse. Concurrent meniscopathy cannot be ruled out. Consider surgical intervention in order to address the presumed biomechanical instability and prevent further damage to the articular structures in the right stifle.

INVOICE

52374

DATE

6-8-22



PATIENT

Yogie Buchanan

SPECIES

Canine

BREED

Spaniel Mix

SEX

Male Neutered

AGE

10 Years

INTERPRETED BY

Nele Eley, DVM
Dr. med. Vet. DipECVDI

HOSPITAL NAME

The Pet Hospital of
Stratford

REFERRING VET

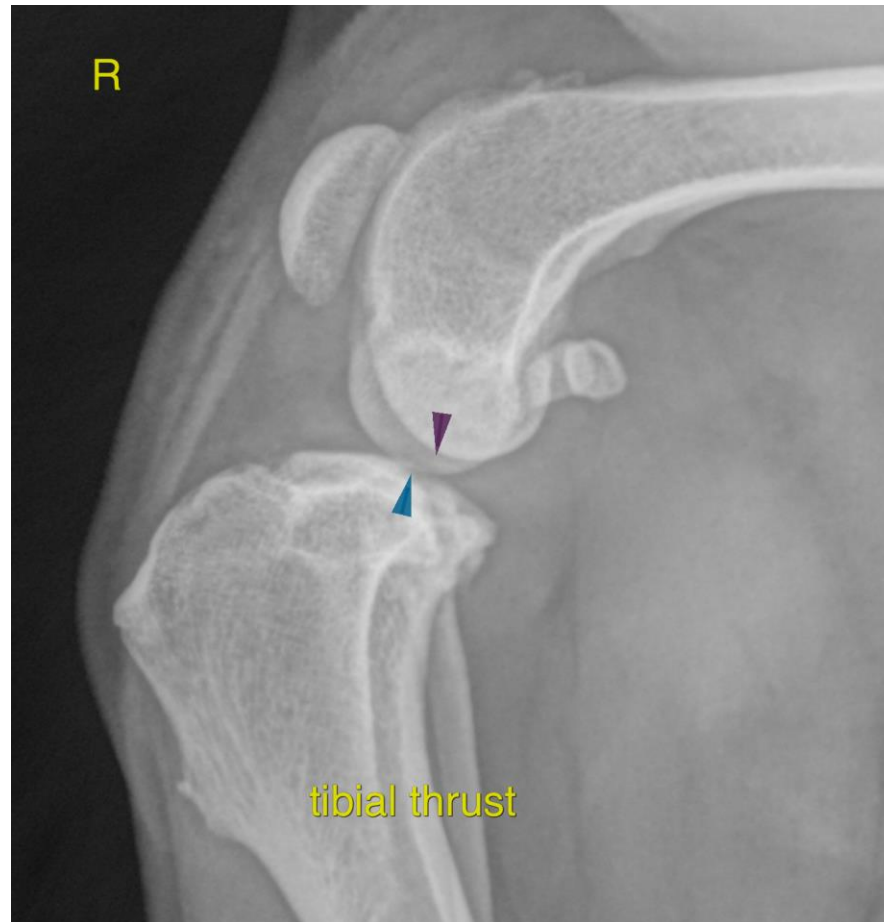
Dr. Claudia Giuliani,
DVM

INVOICE

52374

DATE

6-8-22



The information and recommendations provided are based on the images presented by the referring veterinarian/sonographer. No evaluation can be communicated regarding pathology that was not visible in the image/video clips provided.

Thank you for this referral. If the clinical or image interpretation does not parallel your findings or if I can be of any further assistance please contact me.

Nele Eley, DVM, Dr. med. vet., DipECVDI
European Specialist in Veterinary Diagnostic Imaging, Cert. Radiology,
Senior lecturer University of Giessen, Germany, Veterinary Faculty, Department of Radiology
Nele.Eley@sonopath.com