



PATIENT

Nitro Ferriera

PRESENTING CLINICAL SIGNS

LH lameness - painful stifle RH had TPLO 2 years ago, doing well on that.
Abnormal PE/Chem/CBC/UA Results: WNL

SPECIES

Canine

RADIOGRAPHIC STUDY OF THE STIFLES

Mediolateral and craniocaudal views of both stifles totaling 5 images available for review.

BREED

Lab X

RADIOGRAPHIC FINDINGS

Patient has a history of TPLO of the right stifle two years ago.

SEX

MN

Moderate articular swelling of the right stifle joint is seen. The implant in the proximal tibiae is in situ and intact. Only mild osteoarthritic changes are evident.

Mild atrophy of the right hind limb musculature is noted when compared with the left side.

AGE

6 Years

RADIOGRAPHIC DIAGNOSIS

- Moderate left stifle osteoarthritis.
- History of TPLO of the right stifle with healed osteotomy and mild disuse atrophy of the right hind limb musculature.

INTERPRETED BY

Nele Eley, DVM
Dr. med. Vet. DipECVDI

INTERPRETATION OF THE FINDINGS & FURTHER RECOMMENDATIONS

HOSPITAL NAME

Balmy Beach Pet
Hospital

The radiographic study reveals significant articular enlargement of the left stifle which is likely to represent a combination of synovial swelling and articular effusion. Cranial cruciate ligament injury is one of the most common underlying causes. Other arthropathy including meniscal injury, patella luxation, caudal cruciate ligament injury, arthritis, and more cannot be ruled out entirely but is by far less common. Correlate with the clinical palpation.

REFERRING VET

Dr. Singh

INVOICE

52355

DATE

6-7-22



PATIENT

Nitro Ferriera

SPECIES

Canine

BREED

Lab X

SEX

MN

AGE

6 Years

INTERPRETED BY

Nele Eley, DVM
Dr. med. Vet. DipECVDI

HOSPITAL NAME

Balmy Beach Pet
Hospital

REFERRING VET

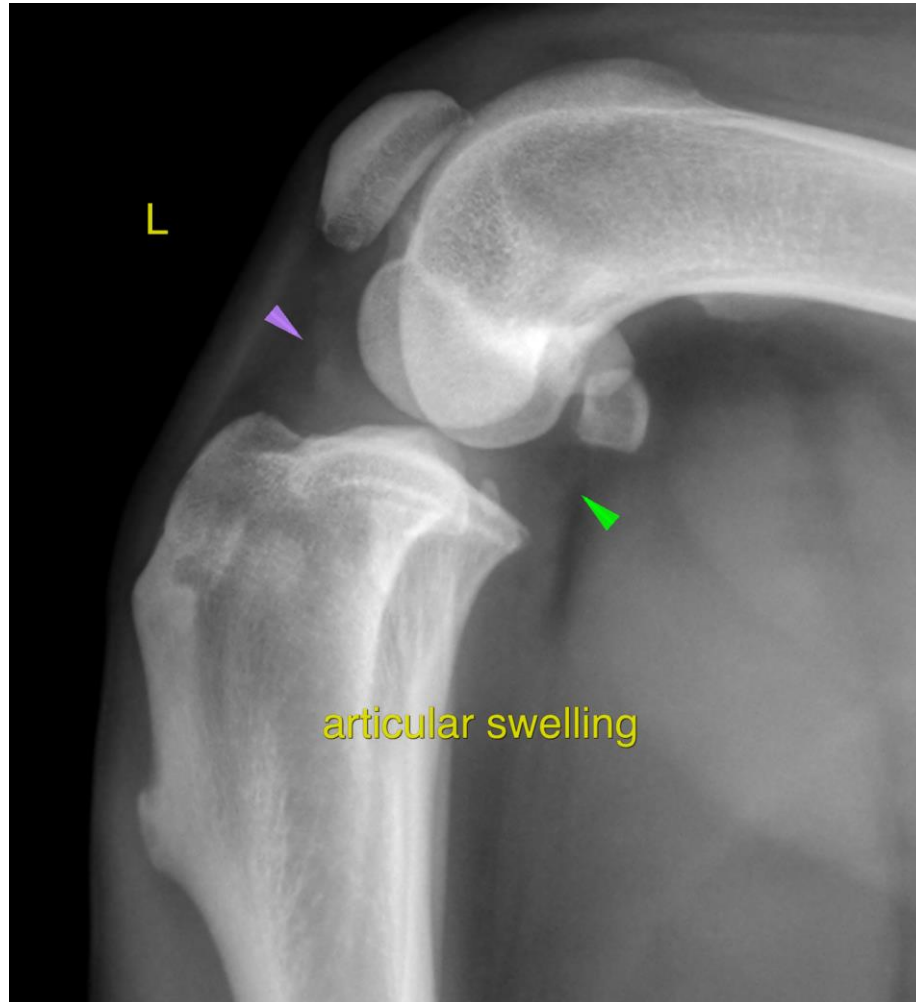
Dr. Singh

INVOICE

52355

DATE

6-7-22



The information and recommendations provided are based on the images presented by the referring veterinarian/sonographer. No evaluation can be communicated regarding pathology that was not visible in the image/video clips provided.

Thank you for this referral. If the clinical or image interpretation does not parallel your findings or if I can be of any further assistance please contact me.

Nele Eley, DVM, Dr. med. vet., DipECVDI
European Specialist in Veterinary Diagnostic Imaging, Cert. Radiology,
Senior lecturer University of Giessen, Germany, Veterinary Faculty, Department of Radiology
Nele.Eley@sonopath.com