



**PATIENT**

Celi Fasanella

**PRESENTING CLINICAL SIGNS**

P presented yesterday for vomiting and diarrhea. O declined diagnostics at that time, elected to do Cerenia injection and take home Probiotic kit. P has not vomited since injection, not eating since Friday. Resists palpation of abdomen. Still having soft stool this morning - O states getting formed but was very black this morning.

**SPECIES**

Canine

**RADIOGRAPHIC STUDY OF THE ABDOMEN**

Right/left lateral and ventrodorsal views totaling 3 images available for review.

**BREED**

Shihtzu Mix

**RADIOGRAPHIC FINDINGS**

The surrounding bony structures are within normal limits.

**SEX**

Female Spayed

No abnormalities of the extraabdominal soft tissues are noted. The abdominal wall is smooth and thin.

The serosal detail is maintained throughout the peritoneal and retroperitoneal space.

**AGE**

2 Years

The liver is appropriate in position, size and presents uniform opacity.

The splenic head is in the anticipated position and within normal limits for size and opacity. The splenic body and tail are considered normal for position, size, shape and opacity.

**INTERPRETED BY**

Nele Eley, DVM  
Dr. med. Vet. DipECVDI

Both kidneys are seen and present with normal size, shape, delineation and opacity. The urinary bladder is in its anticipated position. No radiopaque calculi are noted throughout the upper and lower urinary tract.

The gastrointestinal tract is largely empty. A moderate amount of gas is seen within the stomach.

**HOSPITAL NAME**

The Pet Hospital of  
Stratford

The descending duodenum appears to be fixed in position with predominance of gas content. No evidence of small intestinal dilation, plication, or radiopaque foreign material is noted.

The colon and cecum are seen in their anticipated position.

**REFERRING VET**

Dr. Claudia Giuliani,  
DVM

**RADIOGRAPHIC DIAGNOSIS**

- Gastrointestinal maldigestion pattern - no radiographic evidence of mechanical ileus.

**INTERPRETATION OF THE FINDINGS & FURTHER RECOMMENDATIONS**

The radiographic findings are compatible with functional ileus. There is no evidence of mechanical obstruction. Gastroenteropathy, pancreatopathy, intoxication, dietary indiscretion, and other are potential differential diagnoses. Further definition by means of ultrasound would be indicated in case of recurring or persisting clinical signs.

**INVOICE**

52351

**DATE**

6-7-22



**PATIENT**

Celi Fasanella

**SPECIES**

Canine

**BREED**

Shihtzu Mix

**SEX**

Female Spayed

**AGE**

2 Years

**INTERPRETED BY**

Nele Eley, DVM  
Dr. med. Vet. DipECVDI

**HOSPITAL NAME**

The Pet Hospital of  
Stratford

**REFERRING VET**

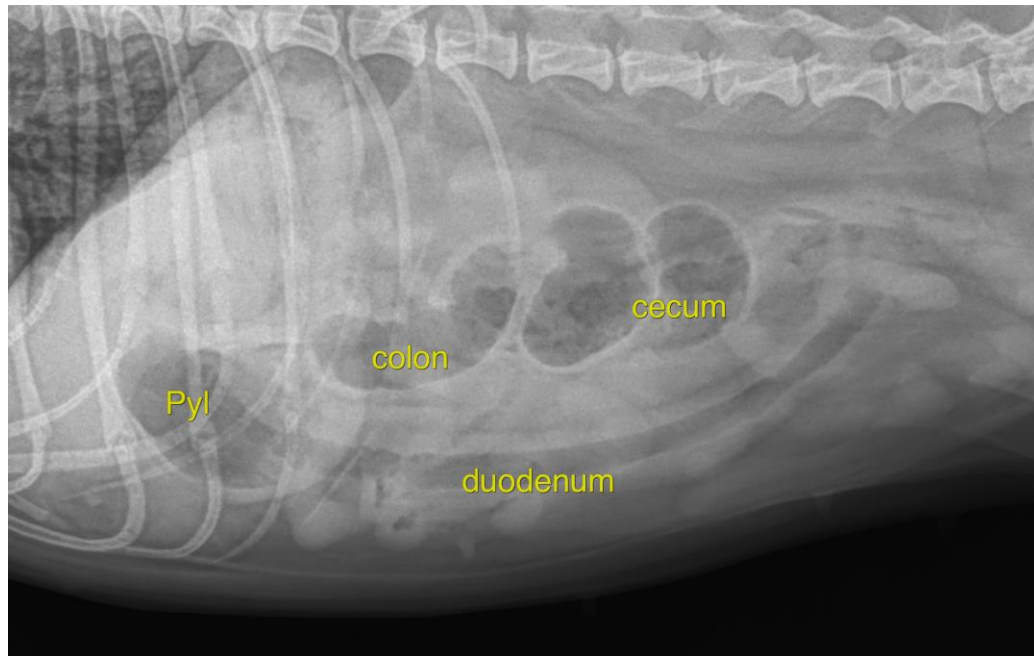
Dr. Claudia Giuliani,  
DVM

**INVOICE**

52351

**DATE**

6-7-22



The information and recommendations provided are based on the images presented by the referring veterinarian/sonographer. No evaluation can be communicated regarding pathology that was not visible in the image/video clips provided.

Thank you for this referral. If the clinical or image interpretation does not parallel your findings or if I can be of any further assistance please contact me.

**Nele Eley**, DVM, Dr. med. vet., DipECVDI  
European Specialist in Veterinary Diagnostic Imaging, Cert. Radiology,  
Senior lecturer University of Giessen, Germany, Veterinary Faculty, Department of Radiology  
Nele.Eley@sonopath.com