



PATIENT

Wilson's Jenkins

PRESENTING CLINICAL SIGNS

Came in for hacking/coughing when the dog gets excited
 Abnormal PE/Chem/CBC/UA Results: wheezes on tracheal auscultation, cough not elicited on tracheal palpation Dehydration basophilia, neutropenia, lymphopenia

SPECIES

Canine

RADIOGRAPHIC STUDY OF THE THORAX

Right/left lateral and ventrodorsal views of the thorax totaling 3 images available for review.

BREED

Terrier Yorkshire Mix

RADIOGRAPHIC FINDINGS

Mild mid thoracic spondylosis deformans is present.

SEX

Male

The tracheal diameter varies between the right and left lateral views in the cervical area. The intrathoracic trachea presents within normal limits.

AGE

6 Years

A mild generalized bronchial lung pattern is noted and evenly distributed throughout the lung. Occasional peribronchial cuffing is seen in the caudodorsal aspect of the lung.

No radiographic evidence of cardiovascular pathology is noted. The vertebral heart score is 10.4.

There is moderate generalized enlargement of the liver with rounded lobar margins.

Moderate gastric aerophagia is present.

INTERPRETED BY

Nele Eley, DVM
 Dr. med. Vet. DipECVDI

RADIOGRAPHIC DIAGNOSIS

- Suspect dynamic tracheal disease.
- Mild bronchial lung pattern.
- Hepatomegaly.
- Aerophagia.

HOSPITAL NAME

St. Catherine's Animal Hospital

INTERPRETATION OF THE FINDINGS & FURTHER RECOMMENDATIONS

The variable diameter of the trachea with redundancy of the dorsal tracheal ligament may be associated with dynamic tracheal disease. Clinical correlation is required.

REFERRING VET

Dr Jui Gokhale

The mild to moderate bronchial lung pattern is evenly distributed and concurred by mild peribronchial cuffing. Consider chronic irritant or allergic bronchitis versus infectious disease such as viral, bacterial, and less likely parasitic. Further definition by means of upper and lower airway endoscopy with airway sampling would be ideal in order to determine the significance of the tracheal diameter changes as well as of the bronchial wall changes seen radiographically.

INVOICE

52322

Differential diagnosis for the hepatomegaly includes metabolic/endocrine hepatopathy. Diffuse inflammatory or neoplastic infiltrates and storage diseases cannot be ruled out entirely but are thought less likely.

DATE

6-6-22

The aerophagia is likely secondary to dyspnea or excitement.



PATIENT

Wilsons Jenkins

SPECIES

Canine

BREED

Terrier Yorkshire Mix

SEX

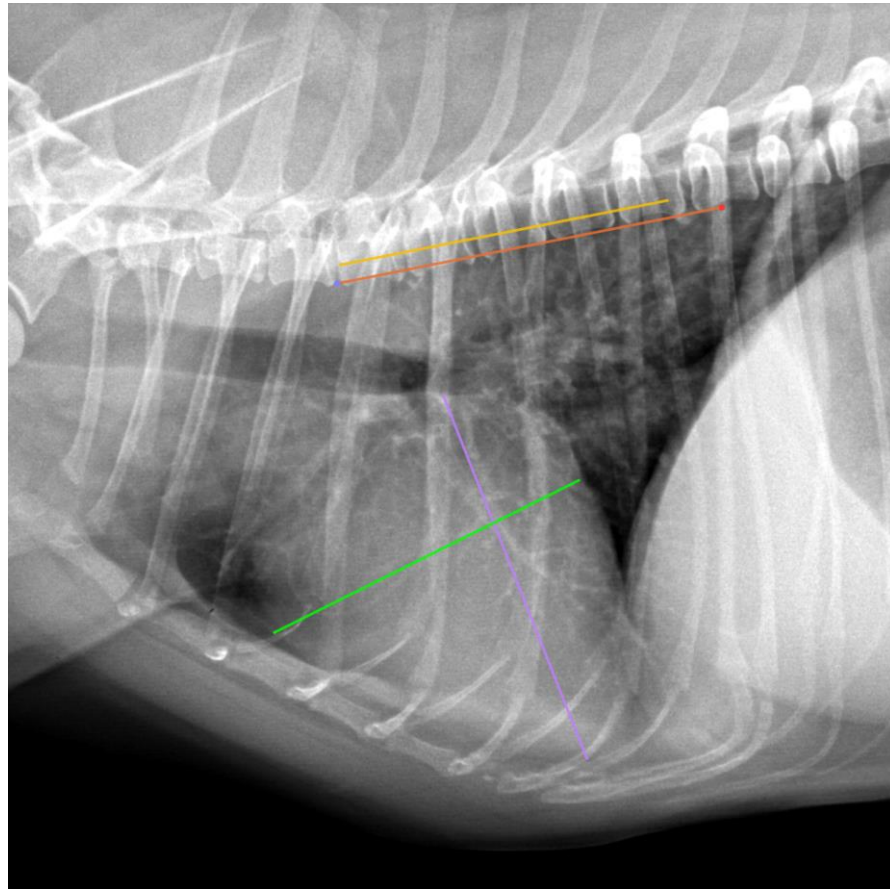
Male

AGE

6 Years

INTERPRETED BY

Nele Eley, DVM
Dr. med. Vet. DipECVDI



HOSPITAL NAME

St. Catherine's Animal
Hospital

REFERRING VET

Dr Jui Gokhale

INVOICE

52322

DATE

6-6-22

The information and recommendations provided are based on the images presented by the referring veterinarian/sonographer. No evaluation can be communicated regarding pathology that was not visible in the image/video clips provided.

Thank you for this referral. If the clinical or image interpretation does not parallel your findings or if I can be of any further assistance please contact me.

Nele Eley, DVM, Dr. med. vet., DipECVDI
European Specialist in Veterinary Diagnostic Imaging, Cert. Radiology,
Senior lecturer University of Giessen, Germany, Veterinary Faculty, Department of Radiology
Nele.Eley@sonopath.com