

**PATIENT**

Maggie Chiles

**SPECIES**

K9

**BREED**

Collie Mix

**SEX**

SF

**AGE**

8 Years, 11 Months

**INTERPRETED BY**Nele Eley, DVM  
Dr. med. Vet. DipECVDI**HOSPITAL NAME**DPC Veterinary  
Hospital**REFERRING VET**

Dr. Rivera

**INVOICE**

52321

**DATE**

6-6-22

**PRESENTING CLINICAL SIGNS**

Maggies has been improving since last visit, did well with rimadyl, bearing some weight on leg now. Gives gaba when p is having a hard time getting around  
Abnormal PE/Chem/CBC/UA Results: MUSC: Partial WB while standing, non-WB to toe-touching on ambulation. + tibial thrust and mild cranial drawer present (pet was tense on palpation/manipulation)

**RADIOGRAPHIC STUDY OF THE RIGHT STIFLE**

Mediolateral and craniocaudal views of the right stifle totaling 2 images available for review.

**RADIOGRAPHIC FINDINGS**

Severe articular enlargement of the right stifle joint is seen.

There is a moderate amount of periarticular osteophytes at the distal pole of the patella, femoral trochlea, fabella, and cranial margin of the tibial plateau.

Significant cranial thrust of the tibia with respect to the distal mid-point of the femoral condyles is seen.

The patella is in situ.

The popliteal lymph node presents within normal limits.

**RADIOGRAPHIC DIAGNOSIS**

- Moderate to severe right stifle osteoarthritis with radiographic evidence of cranial cruciate ligament failure.

**INTERPRETATION OF THE FINDINGS & FURTHER RECOMMENDATIONS**

The radiographic findings suggest the presence of failure of the cranial cruciate ligament function. Moderate to severe concurrent osteoarthritic changes are seen. The presence of concurrent meniscopathy cannot be ruled out. Correlate with the clinical findings and consider surgical intervention in order to address the presumed biomechanical instability and prevent further damage to the articular structures.



**PATIENT**

Maggie Chiles

**SPECIES**

K9

**BREED**

Collie Mix

**SEX**

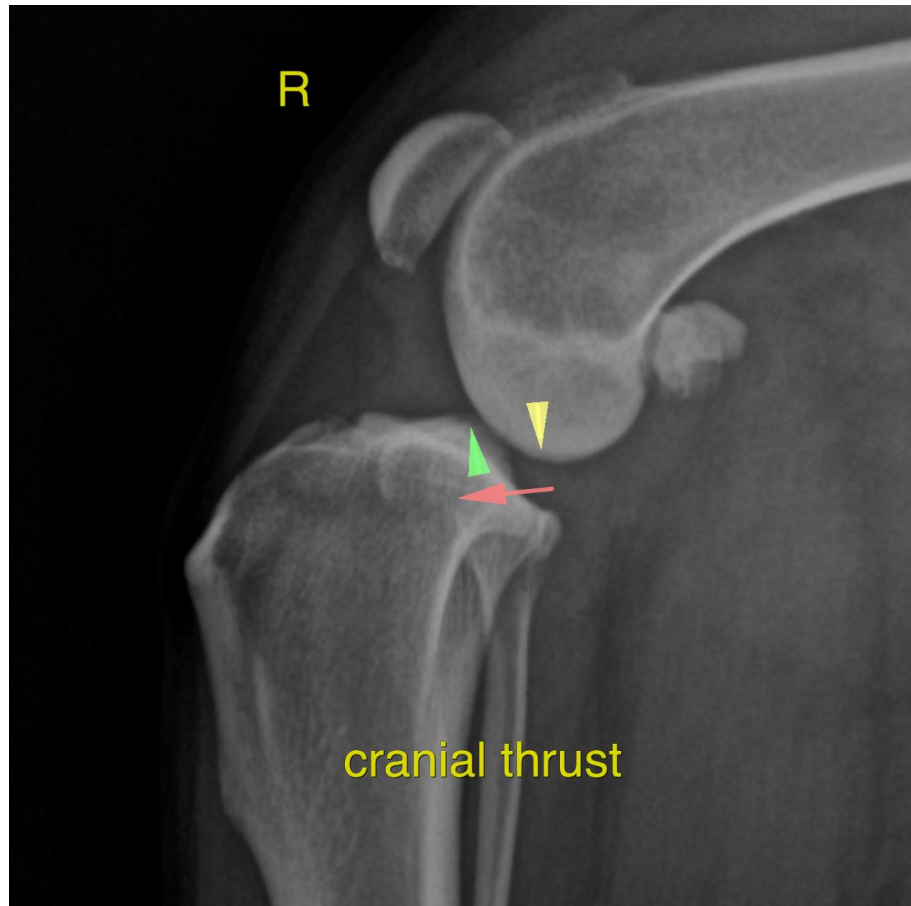
SF

**AGE**

8 Years, 11 Months

**INTERPRETED BY**

Nele Eley, DVM  
Dr. med. Vet. DipECVDI



**HOSPITAL NAME**

DPC Veterinary  
Hospital

**REFERRING VET**

Dr. Rivera

**INVOICE**

52321

**DATE**

6-6-22

The information and recommendations provided are based on the images presented by the referring veterinarian/sonographer. No evaluation can be communicated regarding pathology that was not visible in the image/video clips provided.

Thank you for this referral. If the clinical or image interpretation does not parallel your findings or if I can be of any further assistance please contact me.

**Nele Eley, DVM, Dr. med. vet., DipECVDI**  
European Specialist in Veterinary Diagnostic Imaging, Cert. Radiology,  
Senior lecturer University of Giessen, Germany, Veterinary Faculty, Department of Radiology  
Nele.Eley@sonopath.com